

Pectoralis Major tendon transfer for winging scapula

M.N. Naderi, MD

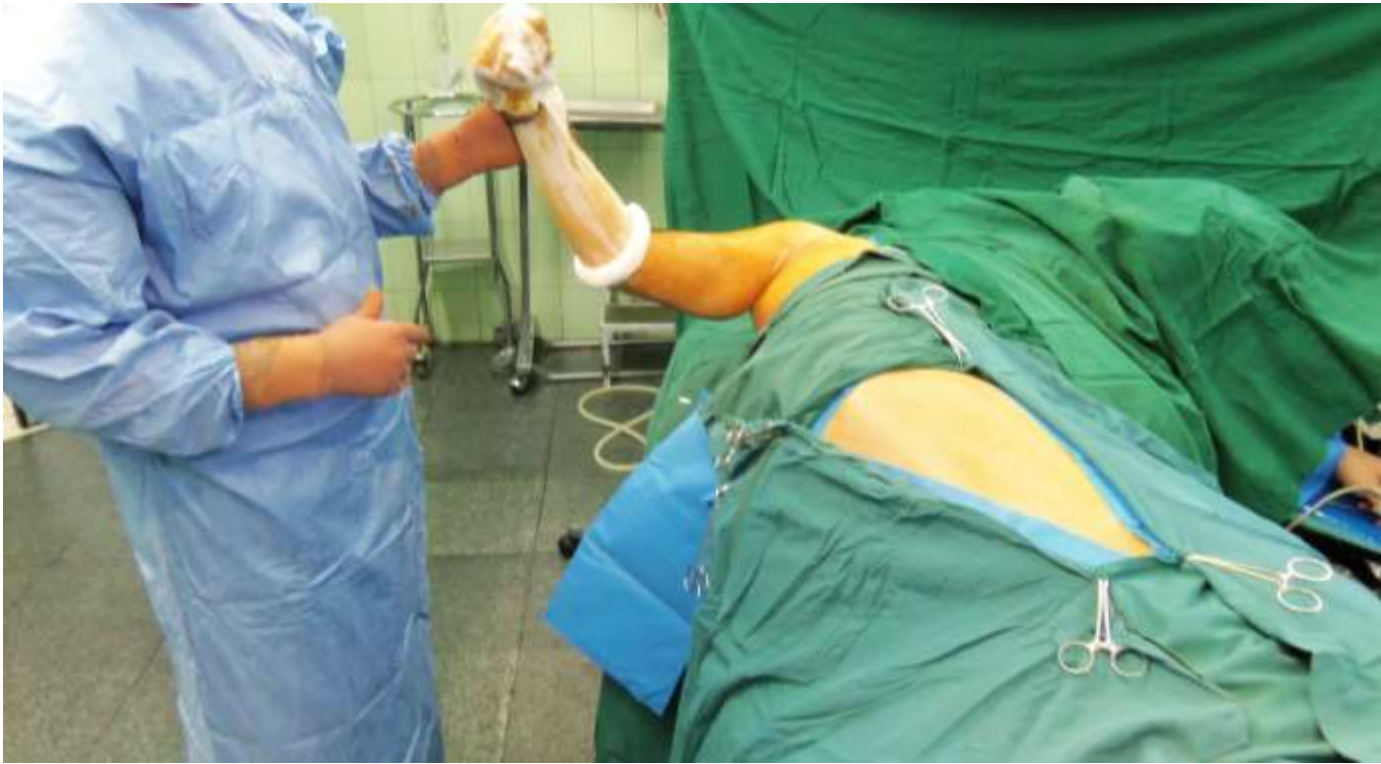Fellowship in shoulder surgery &
arthroscopy

E-mail: nasir.naderi@yahoo.com

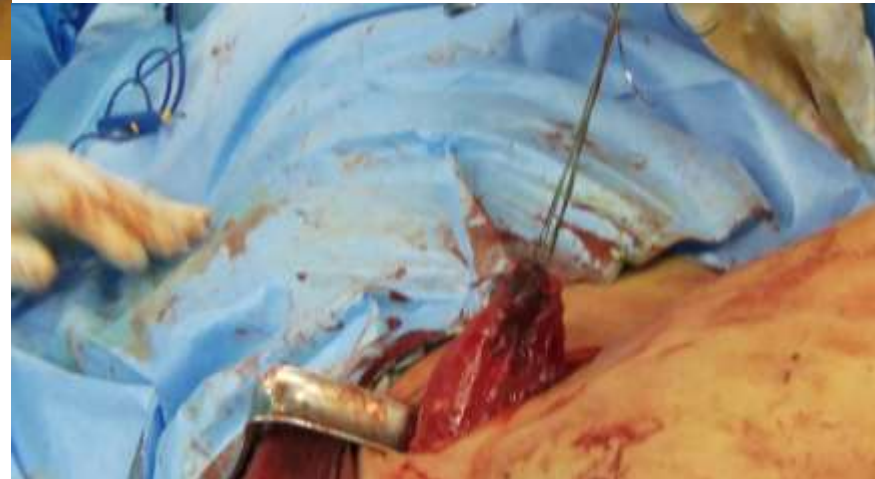
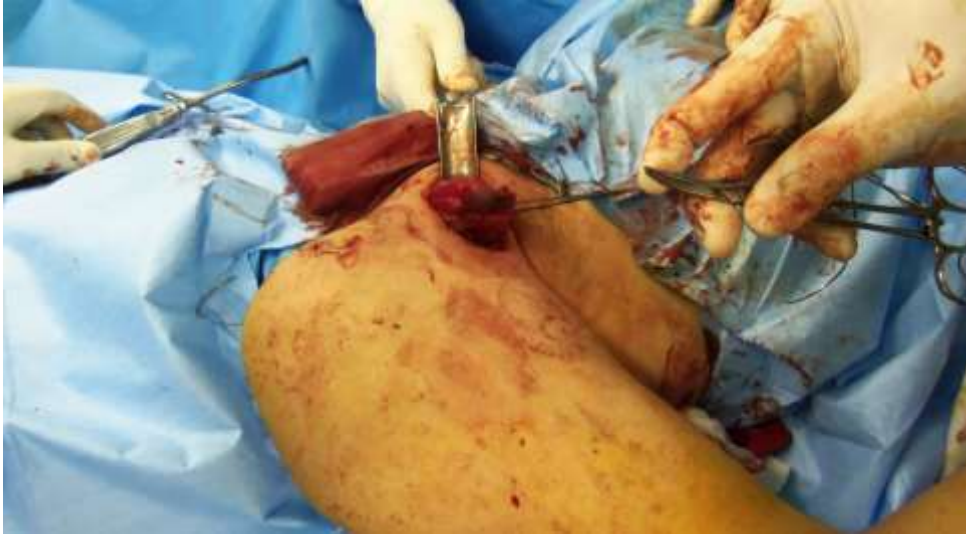Indication

- Winging scapula
 - following long thoracic nerve injury unresponsive to conservative treatment
 - In some cases of muscular dystrophy when the patient is unwilling to scapulothoracic fusion

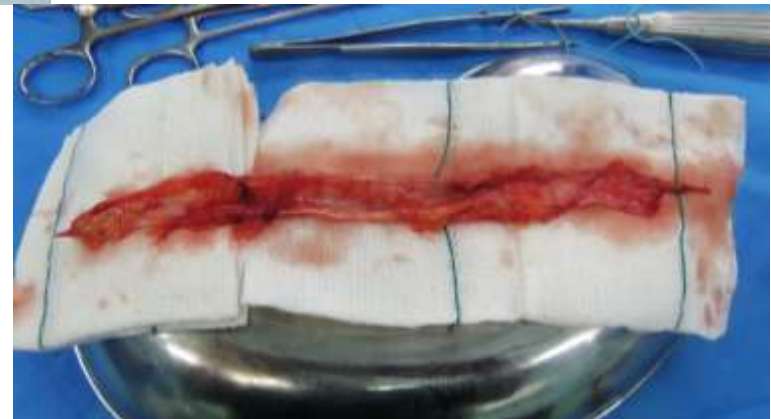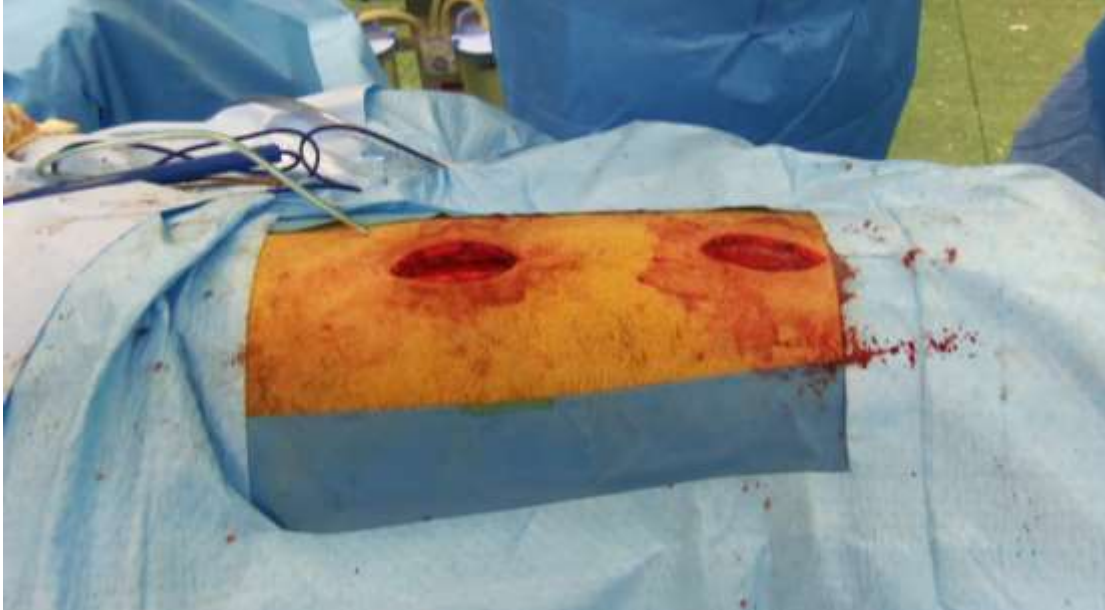Position of patient (lateral decubitus)



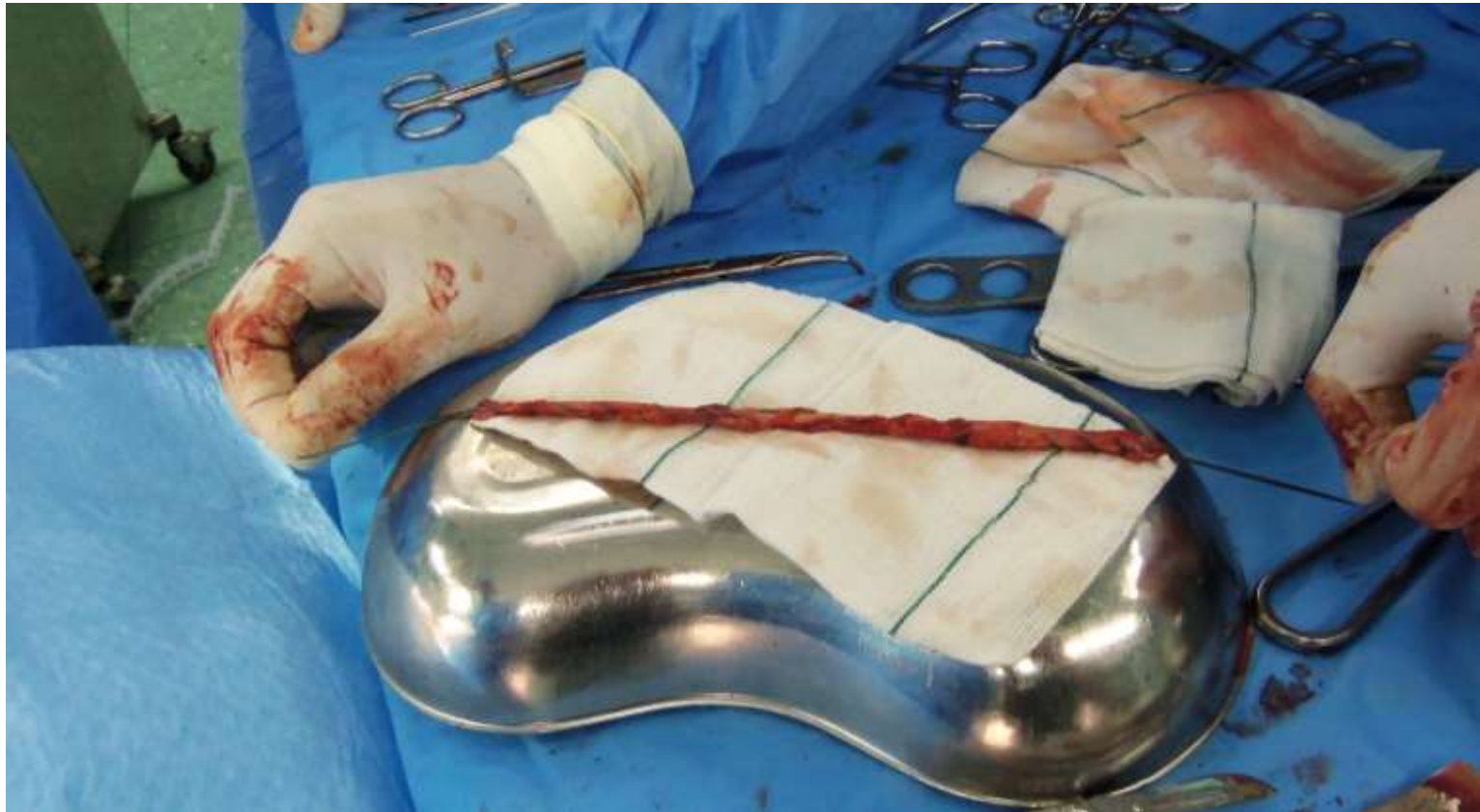Incision in deltopectoral and detaching of Pectoralis major tendon



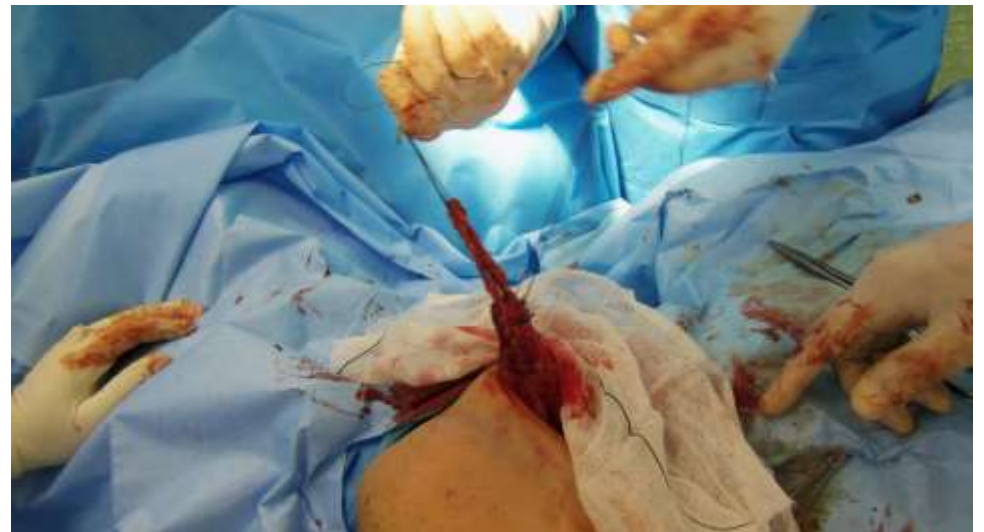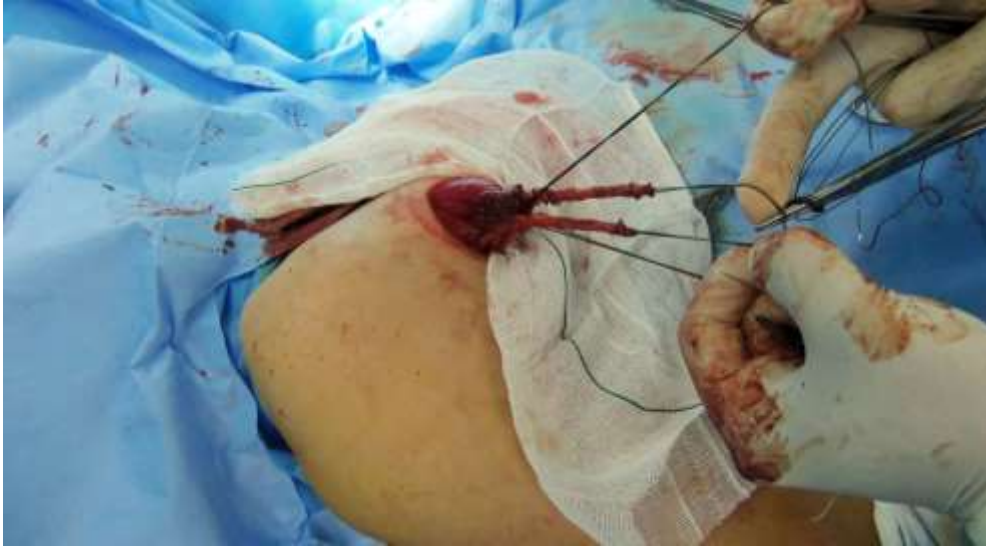Harvesting of fascia lata



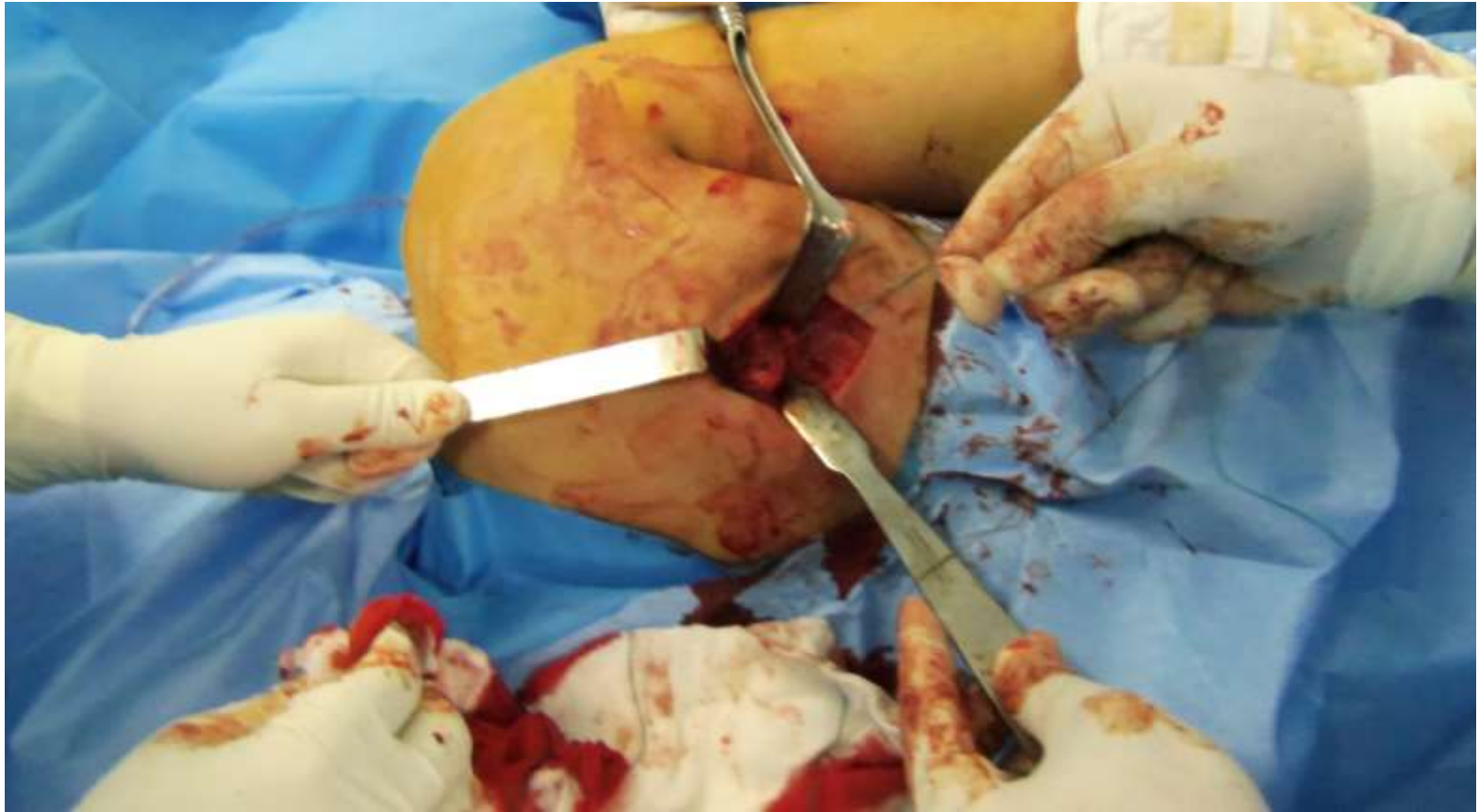
Preparation of harvested tendon



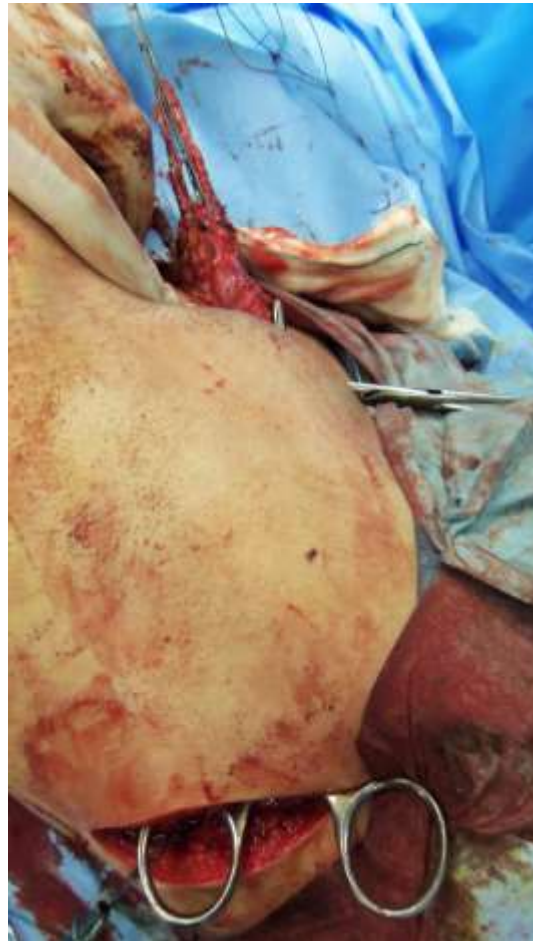Elongation of Pectoralis tendon by harvested tendon



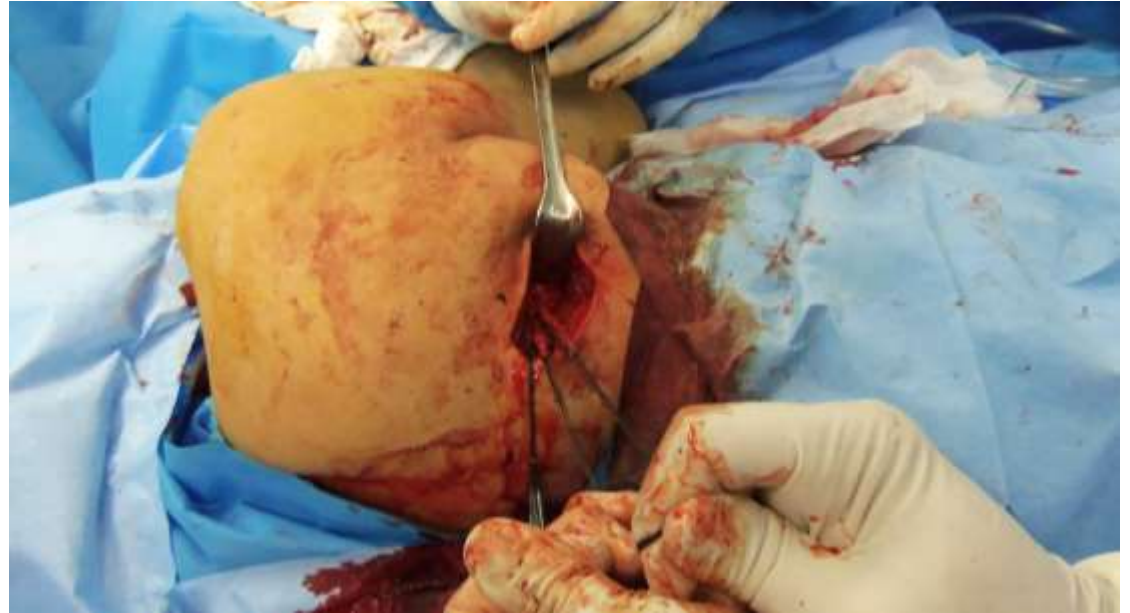
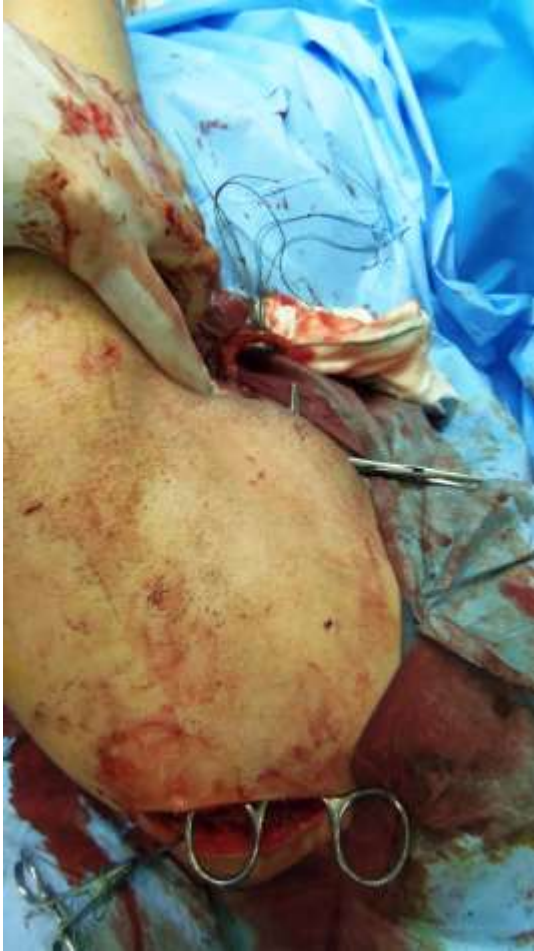Incision of inferior pole of scapula



Making a tunnel between inferior pole of Scapula and Pectoralis major tendon



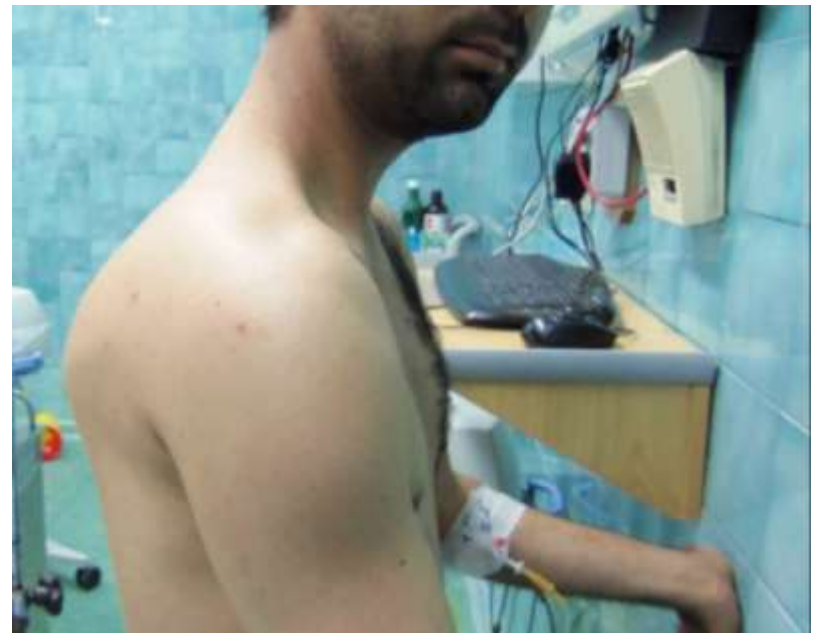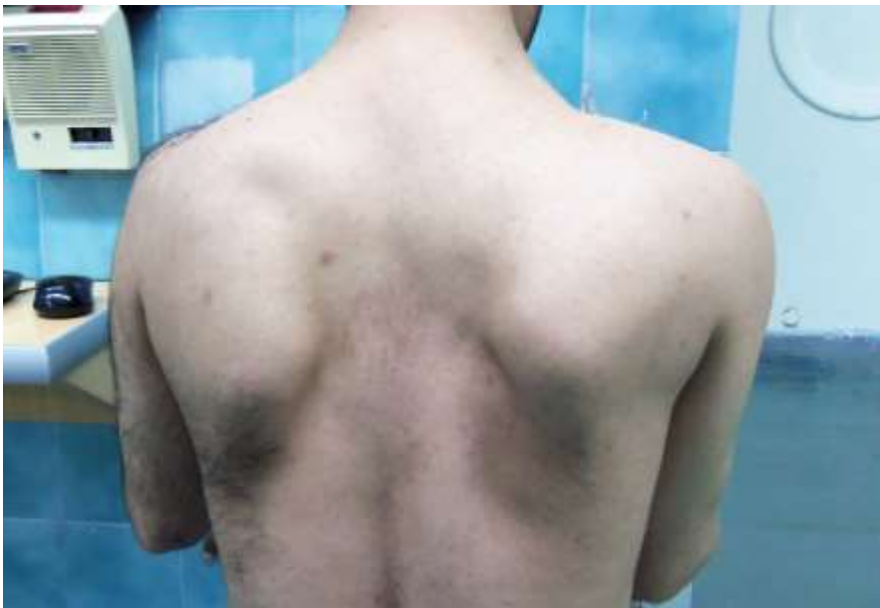Passing of tendon through the tunnel and fixation to inferior pole of scapula



Post op

- Sling for 3- 4 weeks
- Physiotherapy after 4 weeks
 - Active assisted and then active ROM

Pre-Surgery Photo of patient



After 4 month

