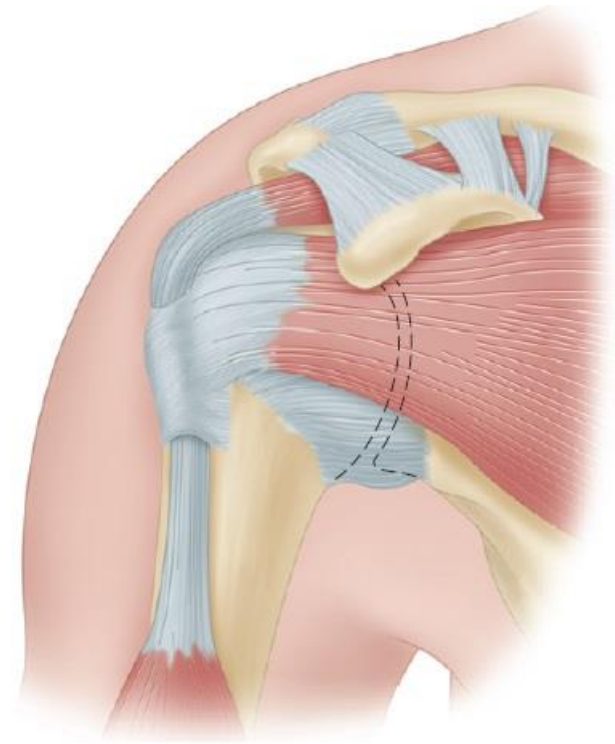


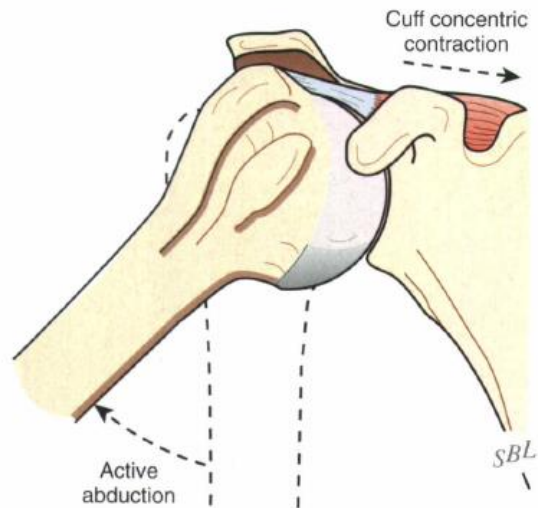
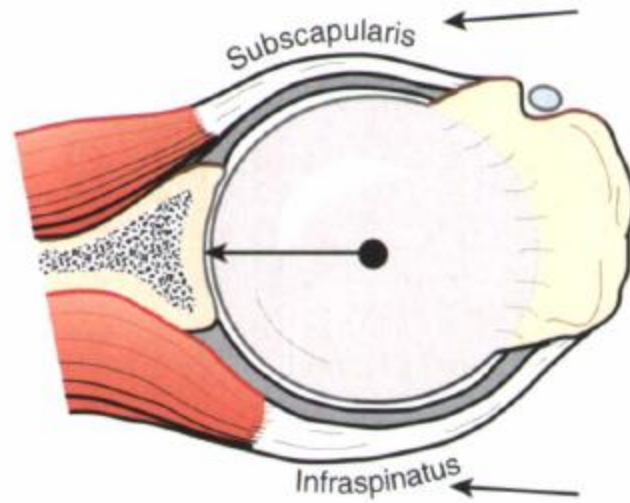
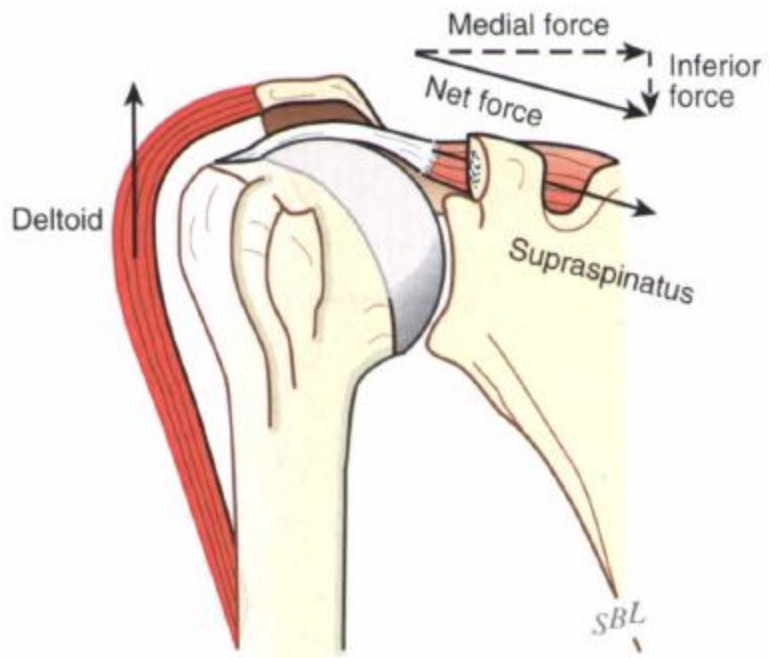


Impingement syndrome

M.N. Naderi , MD

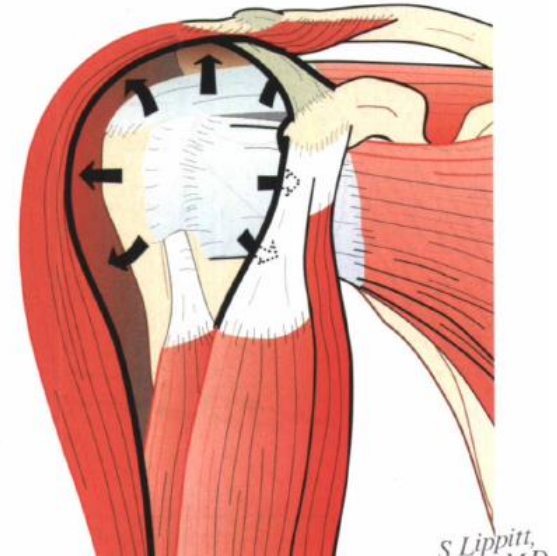
Fellowship in shoulder surgery





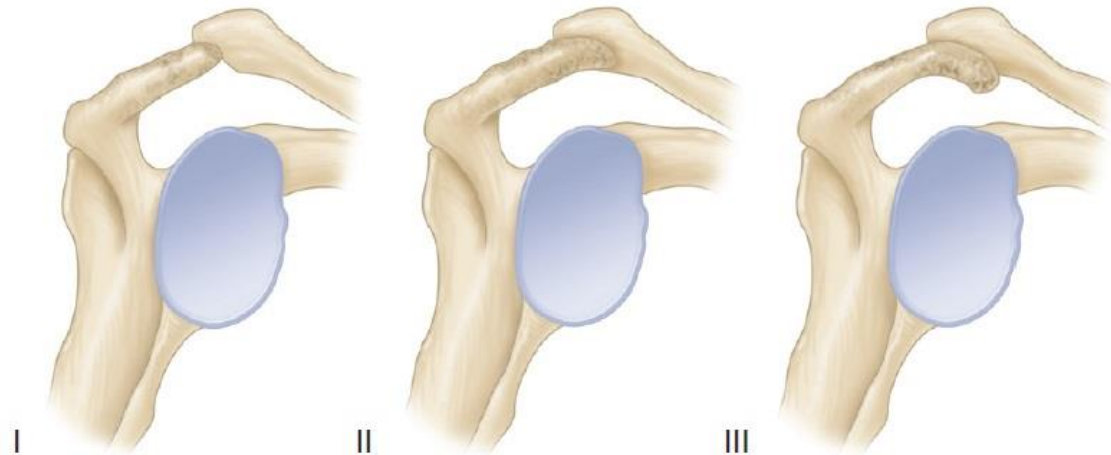
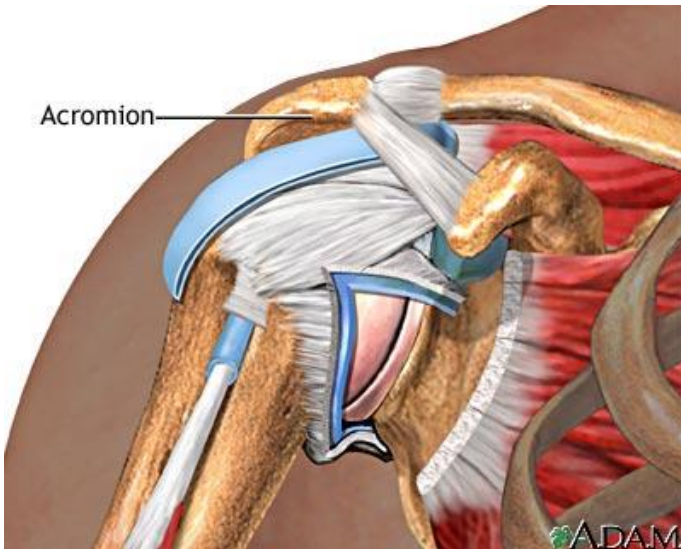
Subtypes of impingement syndrome

- I. primary impingement**
 - a. intrinsic
 - b. extrinsic
- II. secondary impingement**
- III. subcoracoid impingement**
- IV. internal impingement**



□ primary impingement, the classic version

- a. **intrinsic** → structures passing beneath the coracoacromial arch enlarged
- b. **extrinsic types** → space available for the rotator cuff is diminished ;
subacromial spurring, acromial fracture or pathological os acromiale



Stage 1: Edema and Hemorrhage

Typical age of patient: <25 years old

Differential diagnosis: subluxation, acromioclavicular joint arthritis

Clinical course: reversible

Treatment: conservative

Stage 2: Fibrosis and Tendinitis

Typical age of patient: 25 to 40 years old

Differential diagnosis: frozen shoulder, calcium deposits

Clinical course: recurrent pain with activity

Treatment: consider bursectomy or division of coracoacromial ligament

Stage 3: Bone Spurs and Tendon Rupture

Typical age of patient: >40 years old

Differential diagnosis: cervical radiculitis, neoplasm

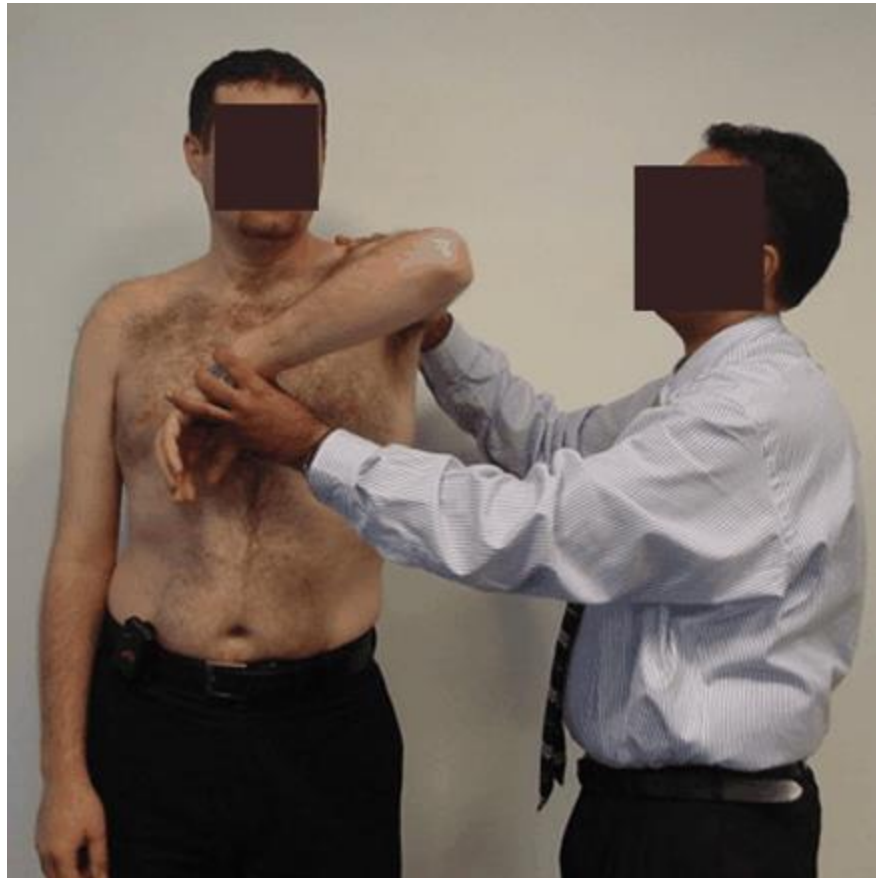Clinical course: progressive disability

Treatment: anterior or acromioplasty, rotator cuff repair

Modified from Neer CS II: Impingement lesions, *Clin Orthop Relat Res* 173: 70, 1983.

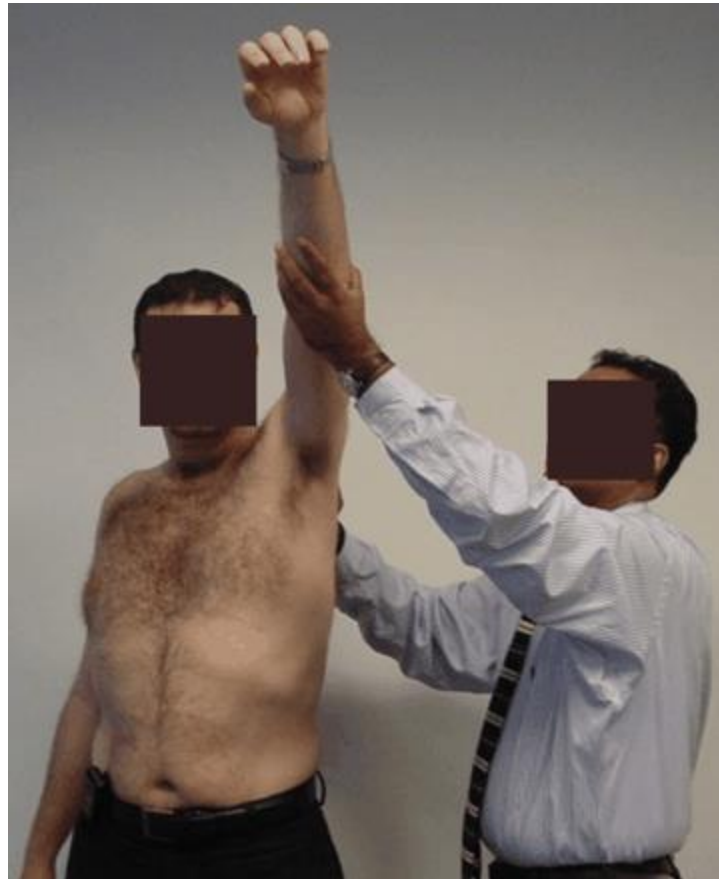○ *Clinical test*

- Hawkin's test
- Neer's sign & test
- Copeland Impingement Test



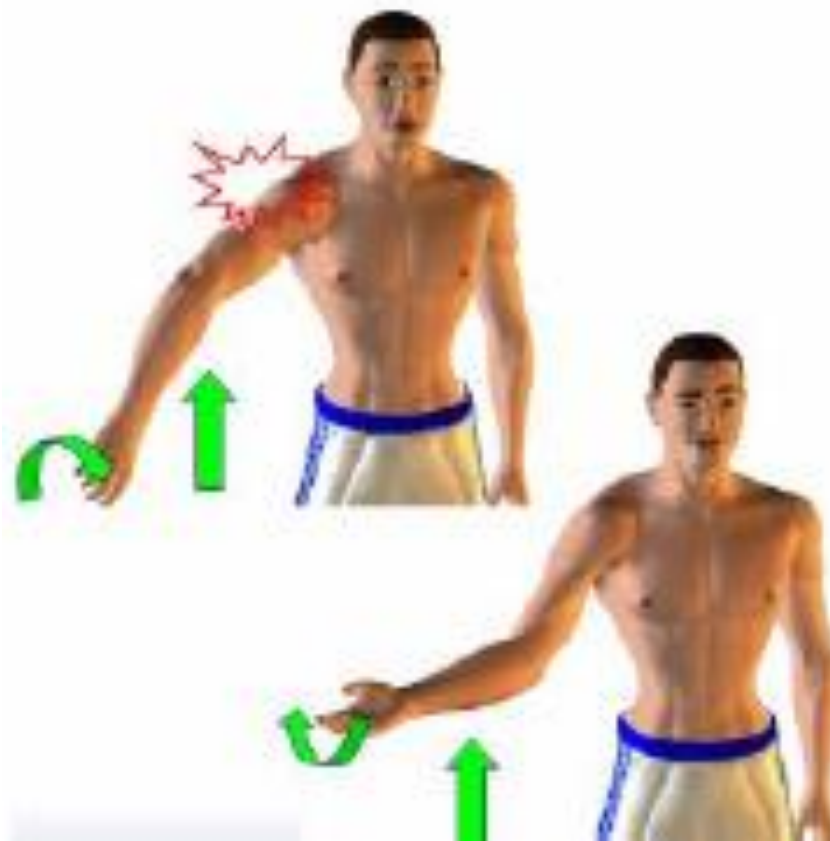
○ ***Clinical test***

- **Hawkin's test**
- **Neer's sign & test**
- **Copeland Impingement Test**



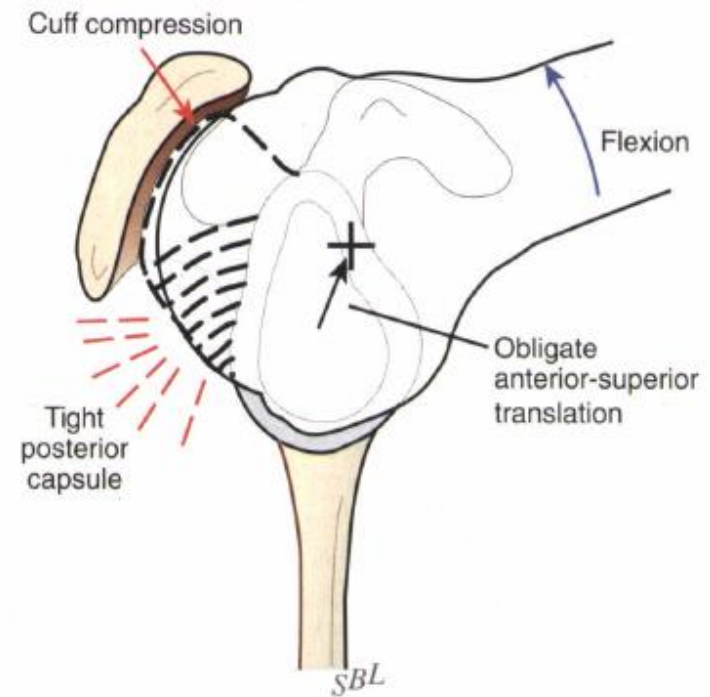
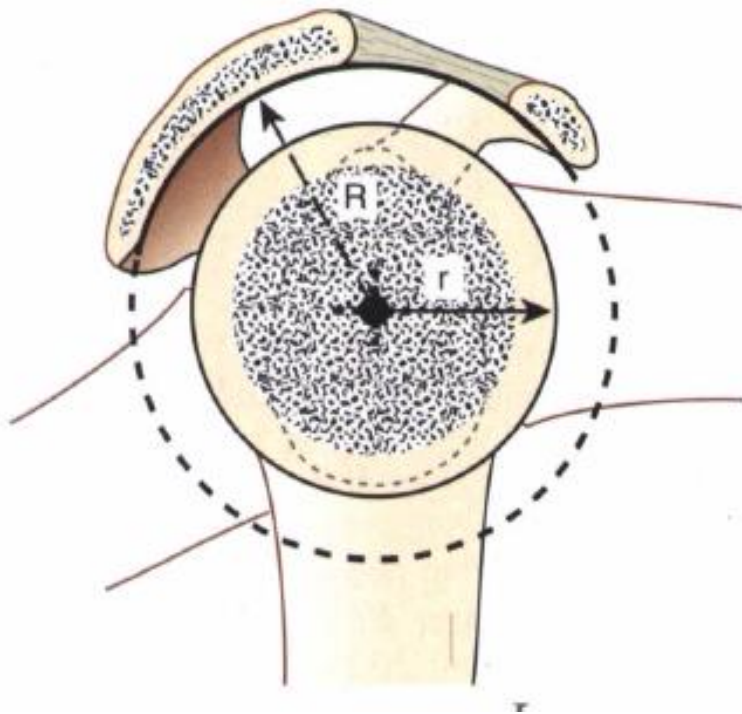
○ *Clinical test*

- Hawkin's test
- Neer's sign & test
- Copeland Impingement Test

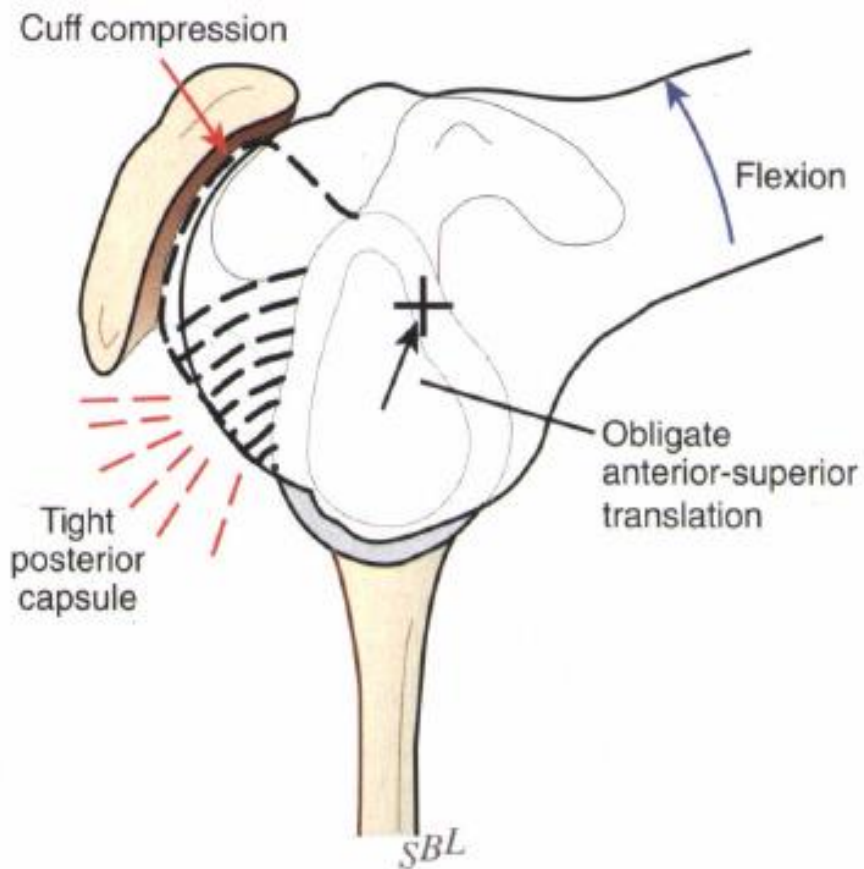
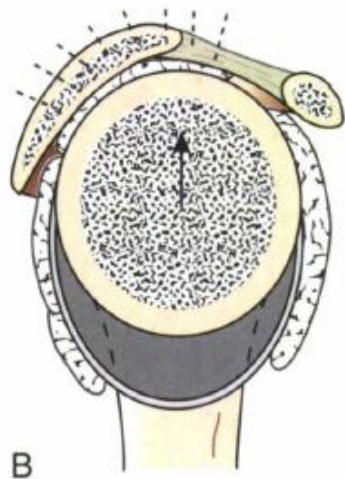
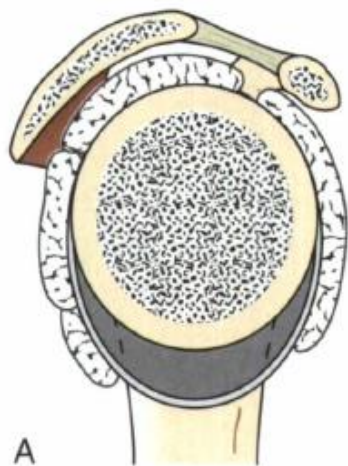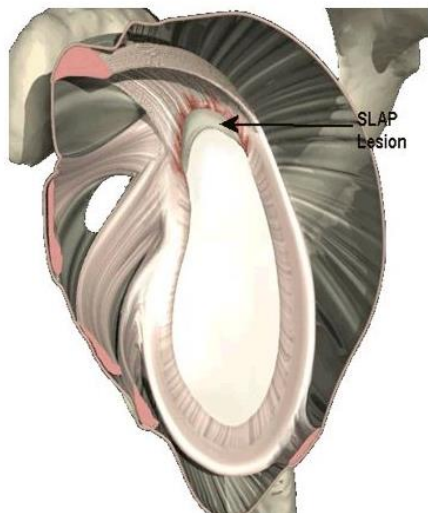


□ secondary impingement

instability of the GH → translation of the humeral head, typically anteriorly, resulting in contact of the rotator cuff against the coracoacromial arch



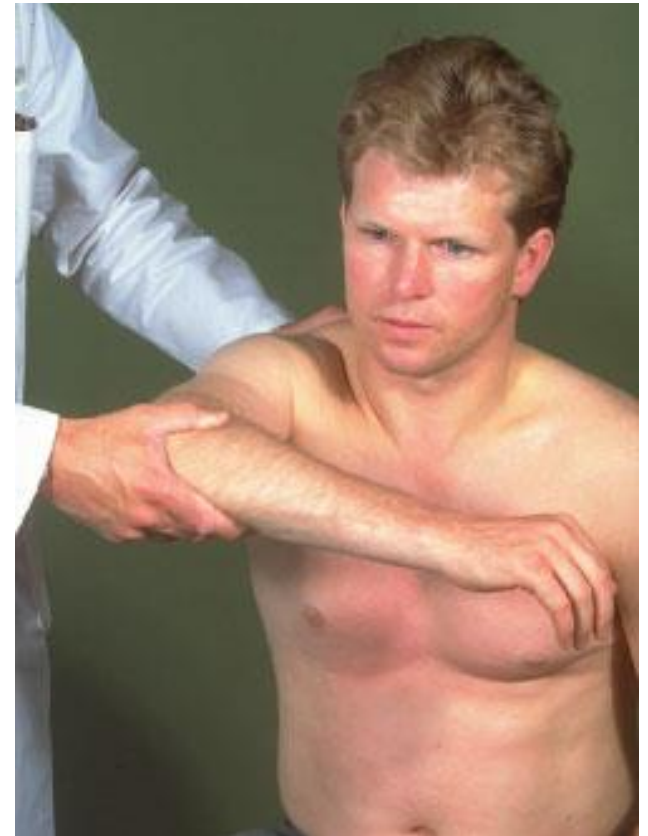
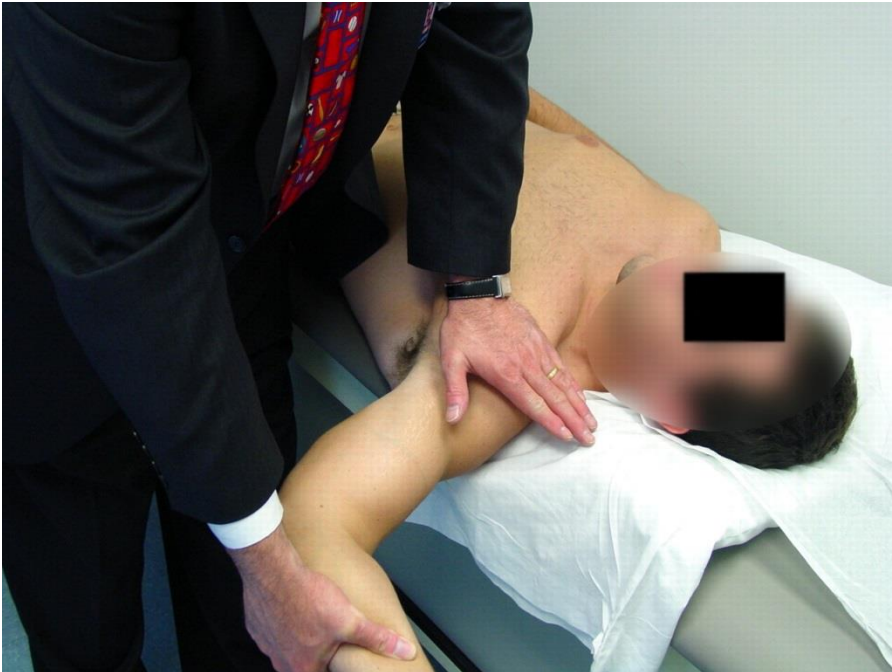□ secondary impingement



□ secondary impingement

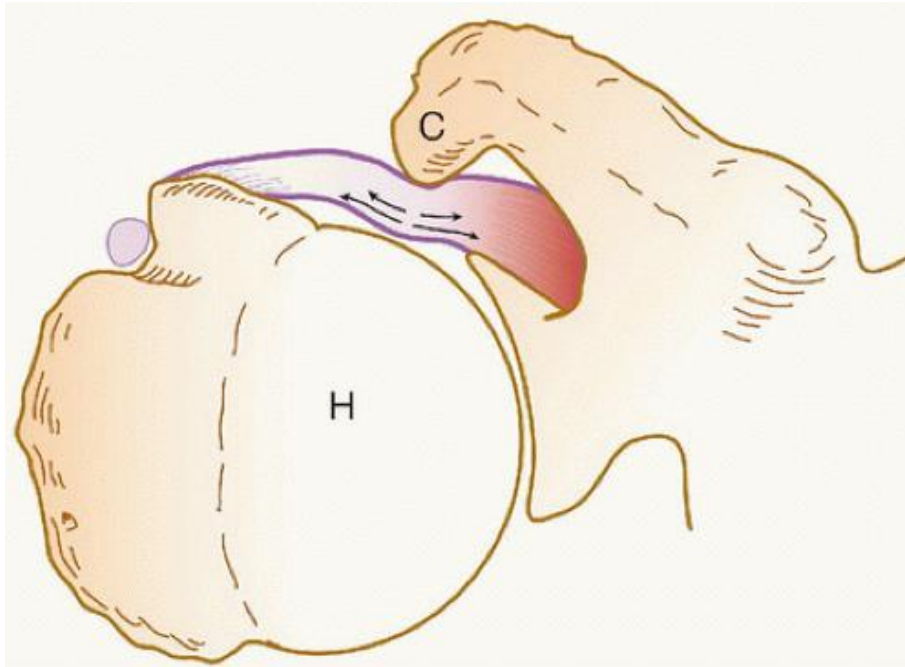
Stability Test

Relocation test (Jobe)



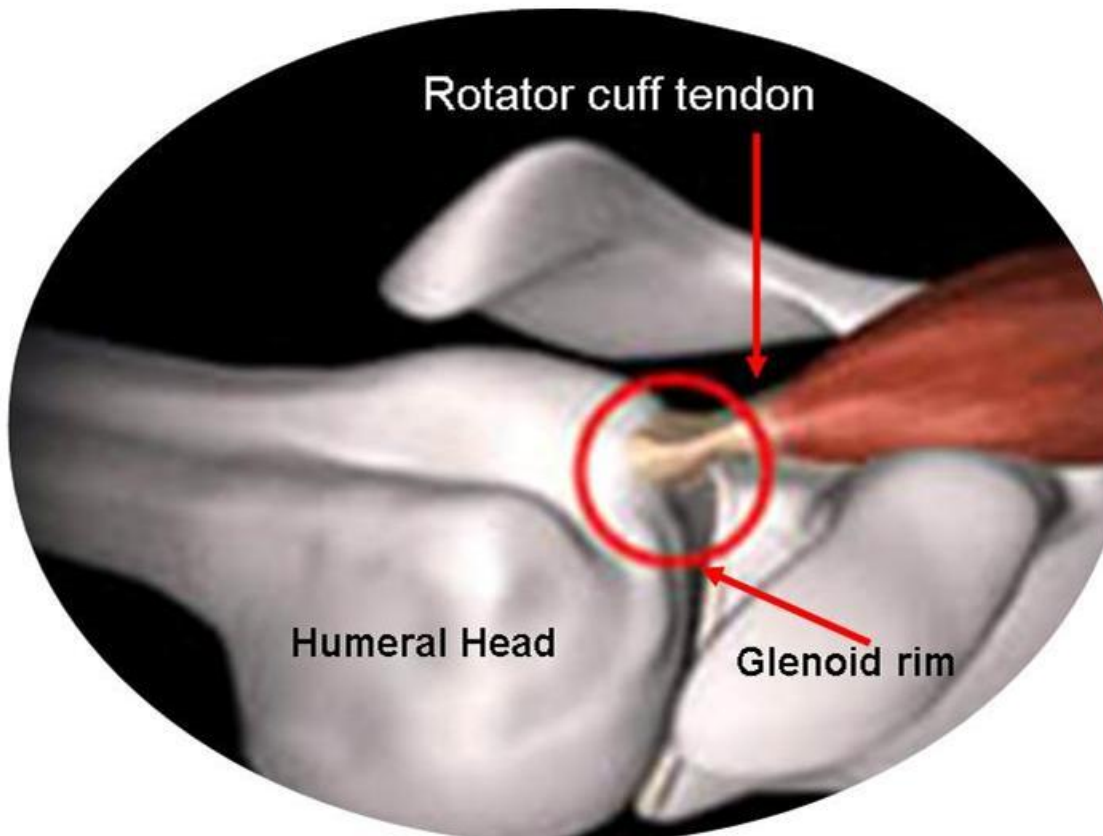
□ subcoracoid impingement

contact between the rotator cuff and the coracoid process




❑ Internal Impingement

- Impingement of postero-superior cuff on the postero-superior labrum



❑ Internal Impingement

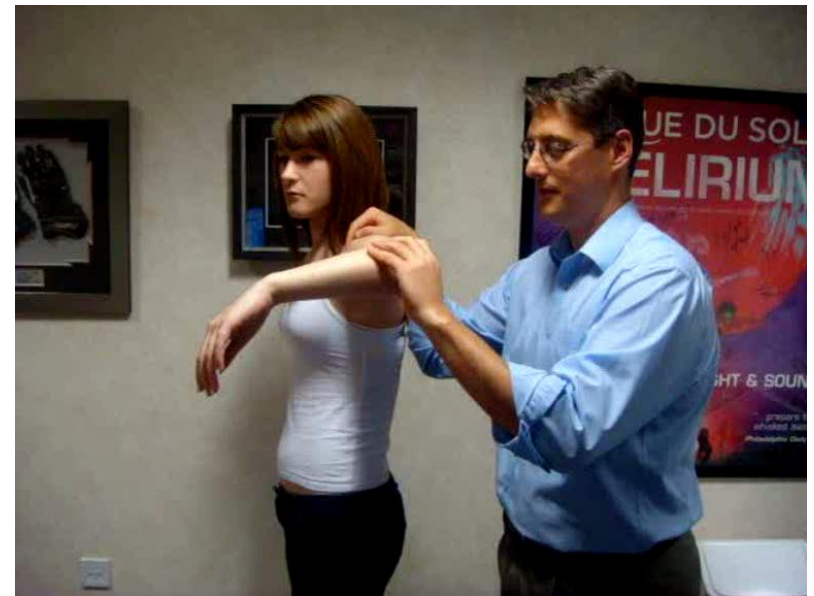Overhead Athlete



❑ Internal Impingement

Diagnosis

- Anterior Laxity without frank instability
- Posterior Capsular Tightness (GIRD)
- Hyperabduction reproduction pain
- Scapula Dyskinesis
- Impingement Tests

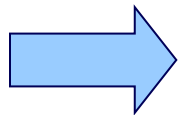


Treatment for Impingement



Physiotherapy

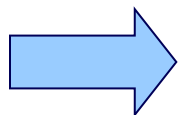

Injection (subacromial)



Surgery
+ Physiotherapy

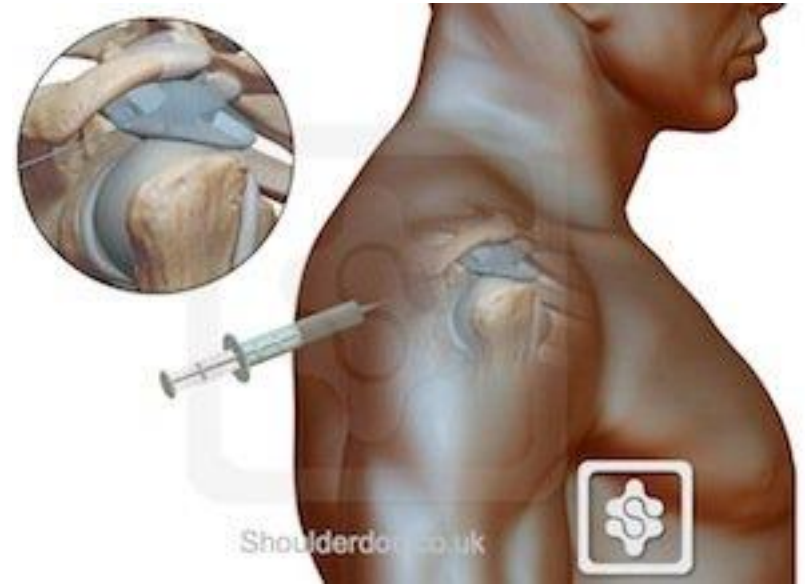Treatment for Impingement

- Physiotherapy**
- Stretching Exercise
 - Stabilization Exercise
- Injection (subacromial)**



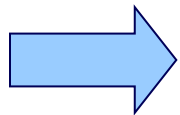
Surgery
+ Physiotherapy

Treatment for Impingement



Physiotherapy

Injection (subacromial)

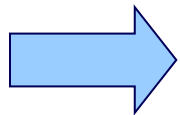


Surgery
+ Physiotherapy

Treatment for Impingement

Physiotherapy

Injection (subacromial)



Surgery
+ Physiotherapy

