


Reverse shoulder prosthesis, Technique

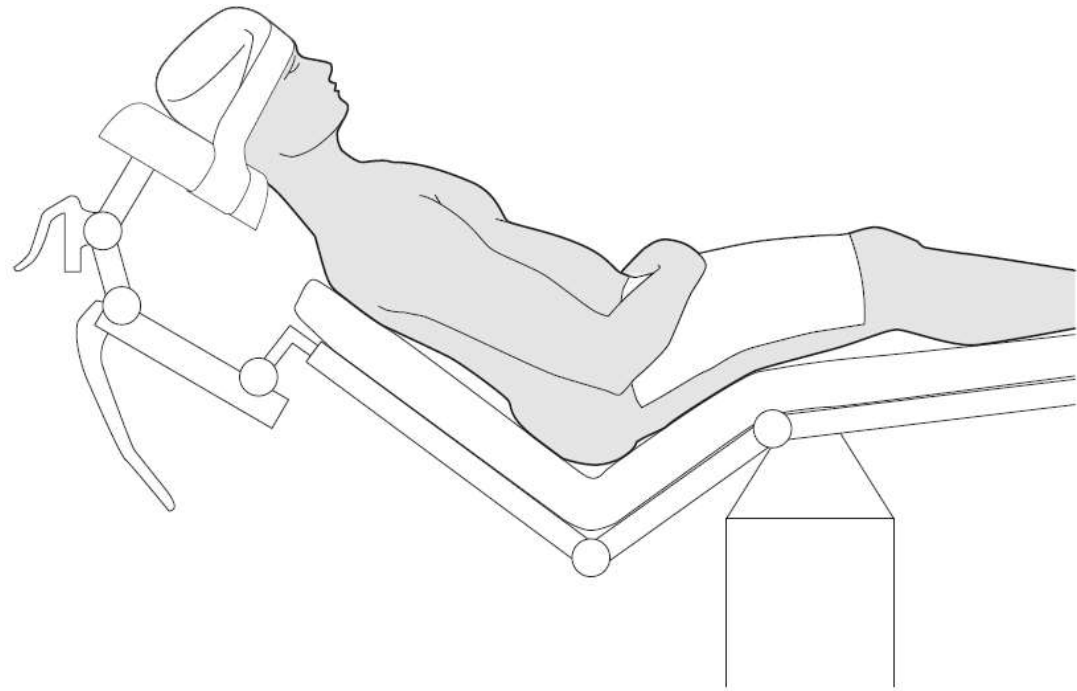
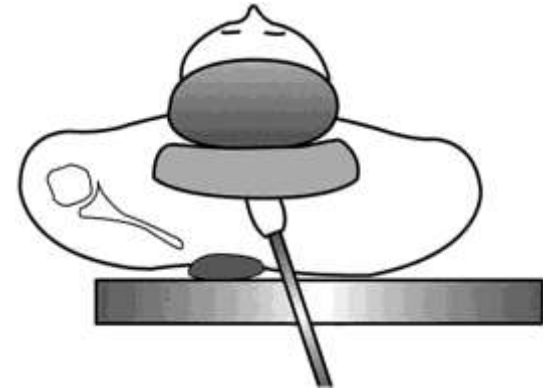
M.N. Naderi, MD

Fellowship in shoulder &
arthroscopic surgery



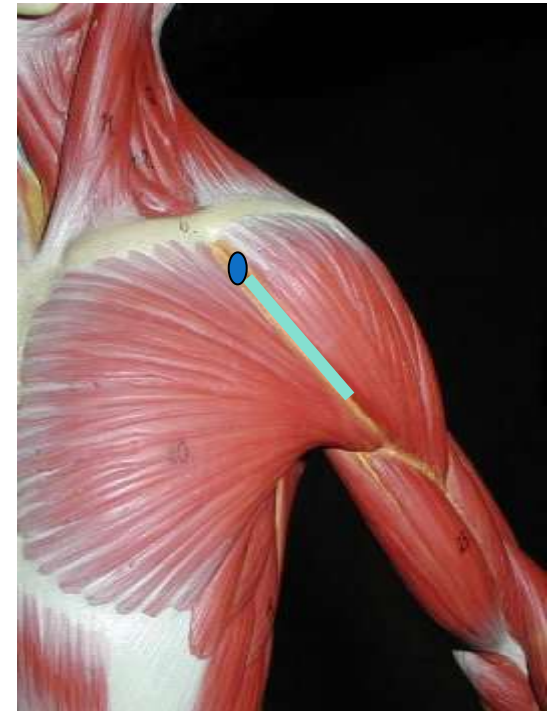
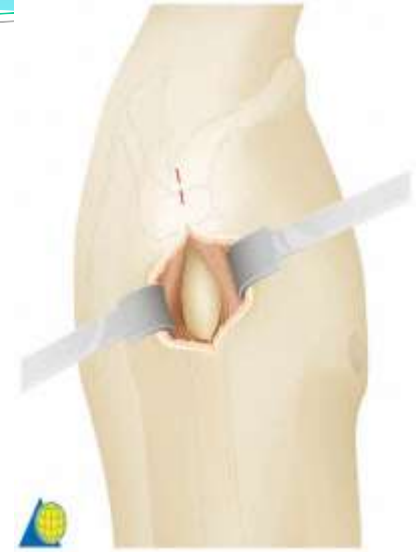Technique

- Positioning
- Approach
- Exposure
- Humeral part
- Glenoid part
- Soft Tissue closure



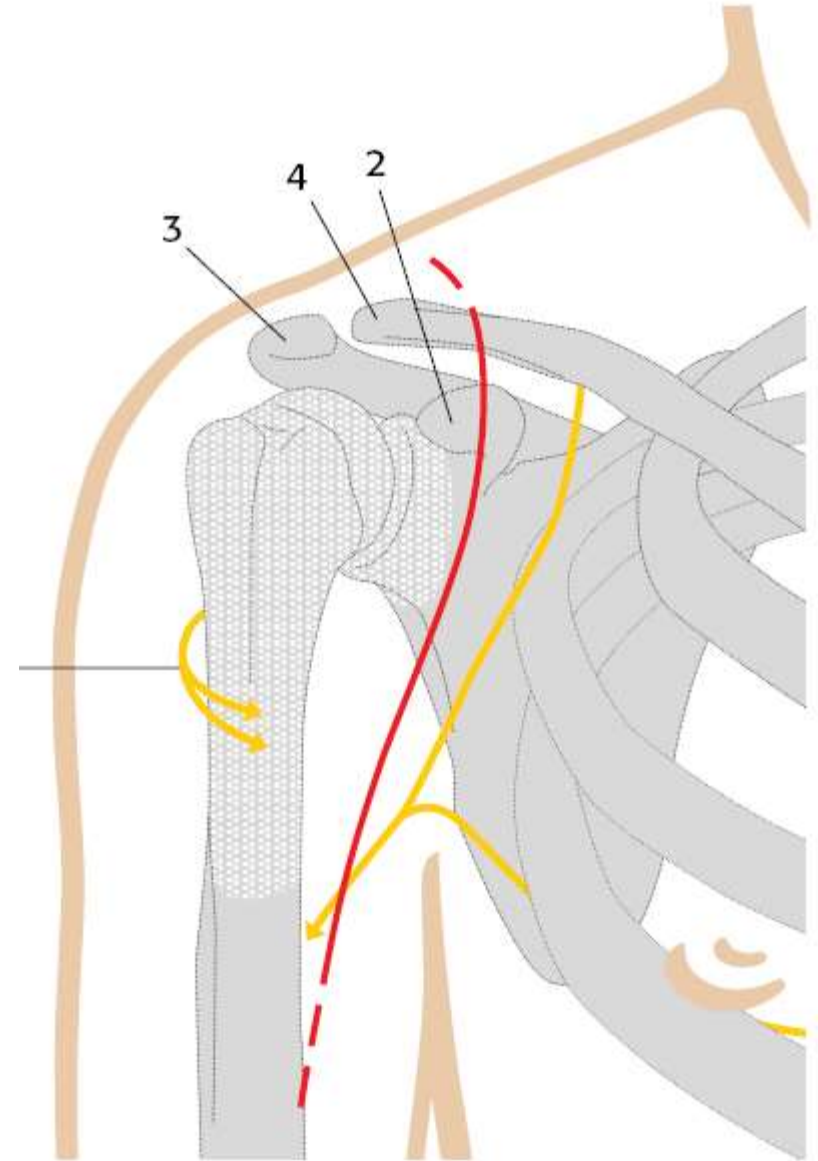
Technique

- Positioning
- Approach
- Exposure
- Humeral part
- Glenoid part
- Soft Tissue closure



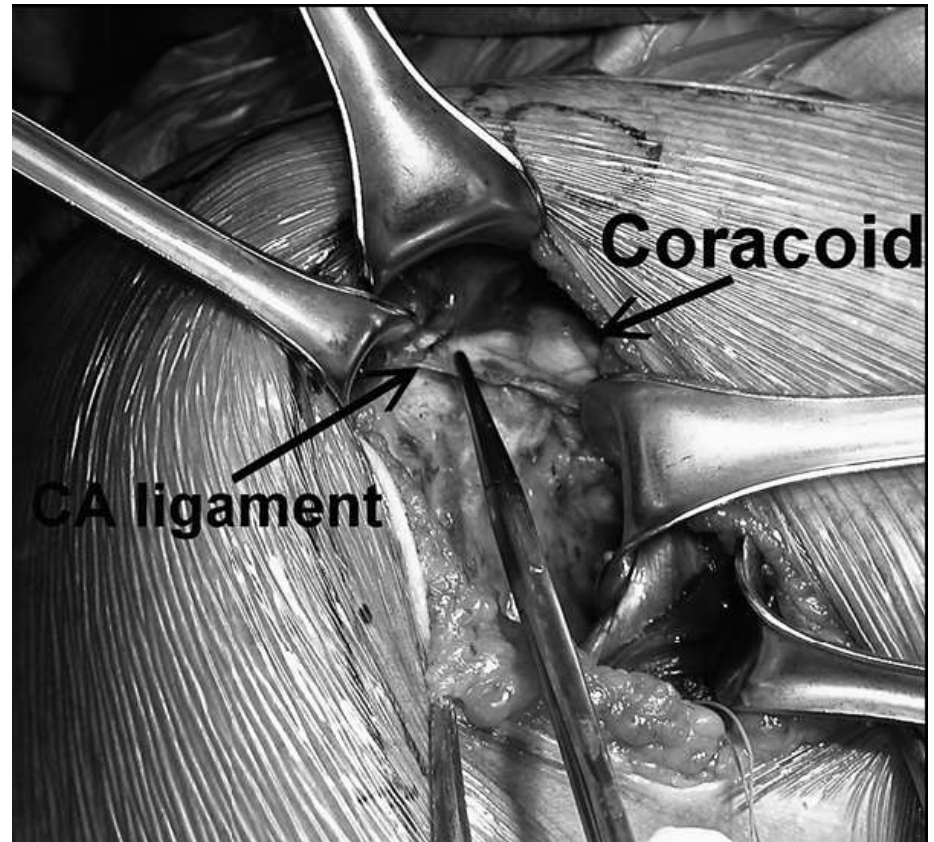
Technique

- Positioning
- Approach
- Exposure
- Humeral part
- Glenoid part
- Soft Tissue closure



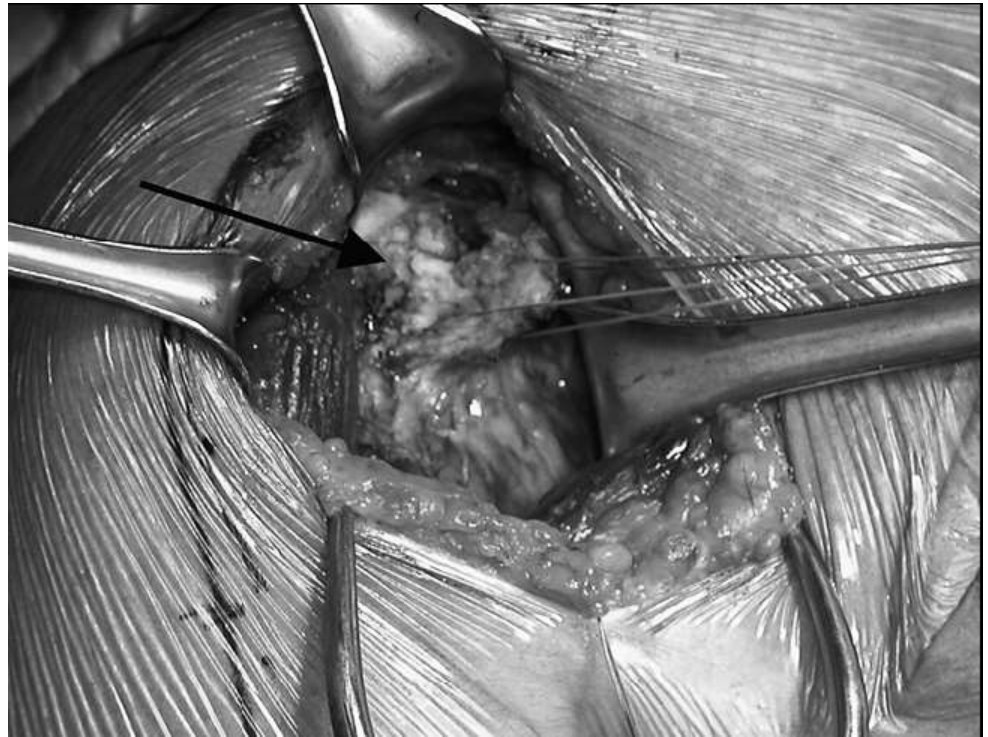Technique

- Positioning
- Approach
- **Exposure**
- Humeral part
- Glenoid part
- Soft Tissue closure



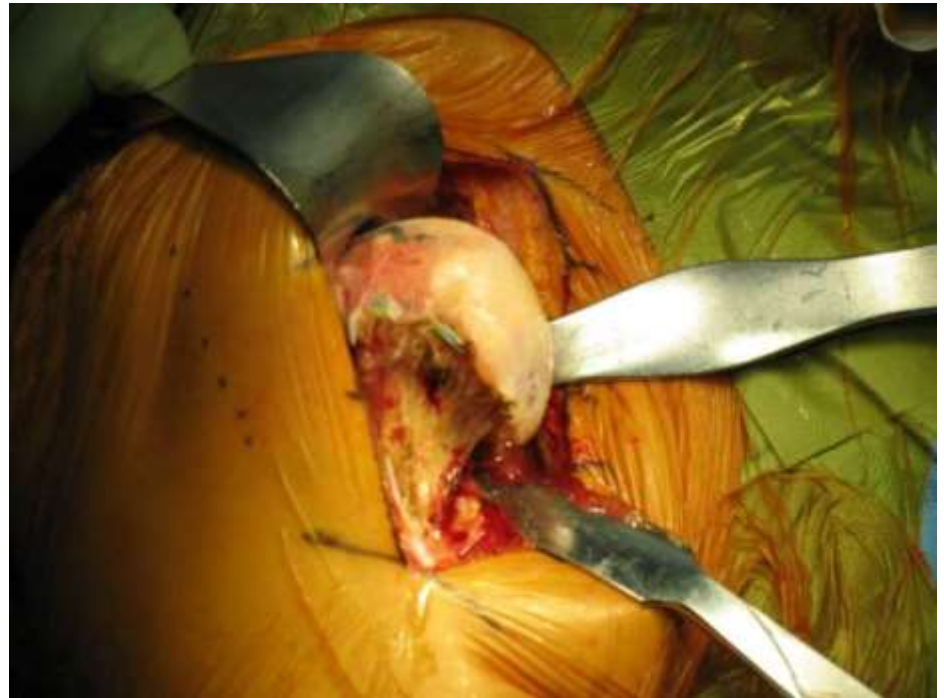Technique

- Positioning
- Approach
- **Exposure**
- Humeral part
- Glenoid part
- Soft Tissue closure



Technique

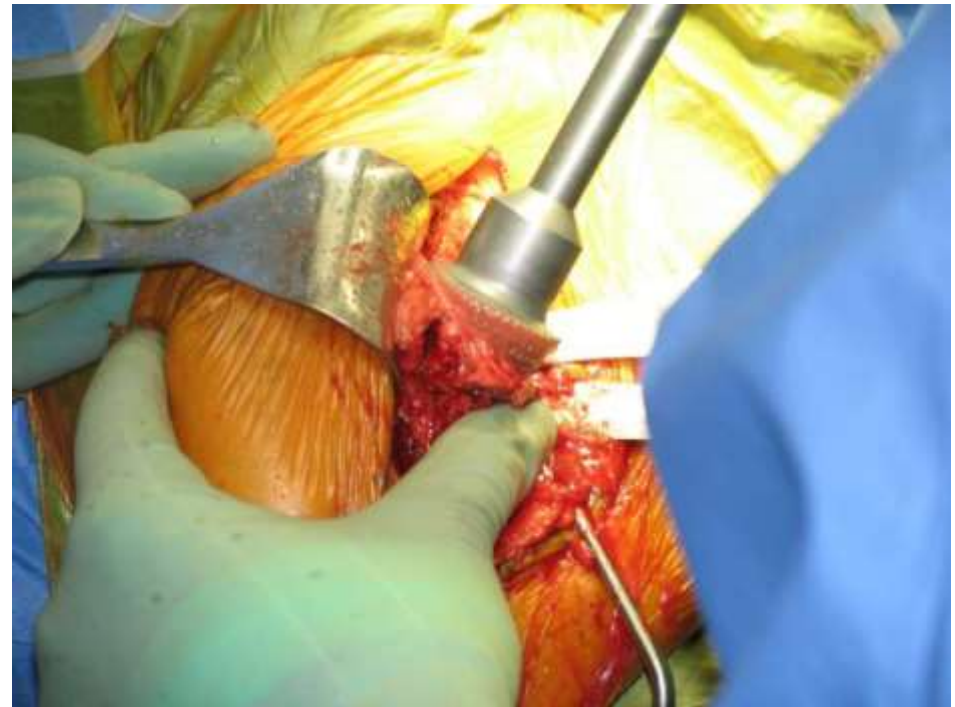
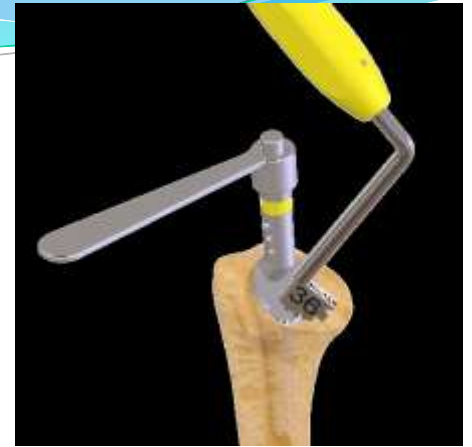- Positioning
- Approach
- Exposure
- **Humeral part**
- Glenoid part
- Soft Tissue closure



Technique

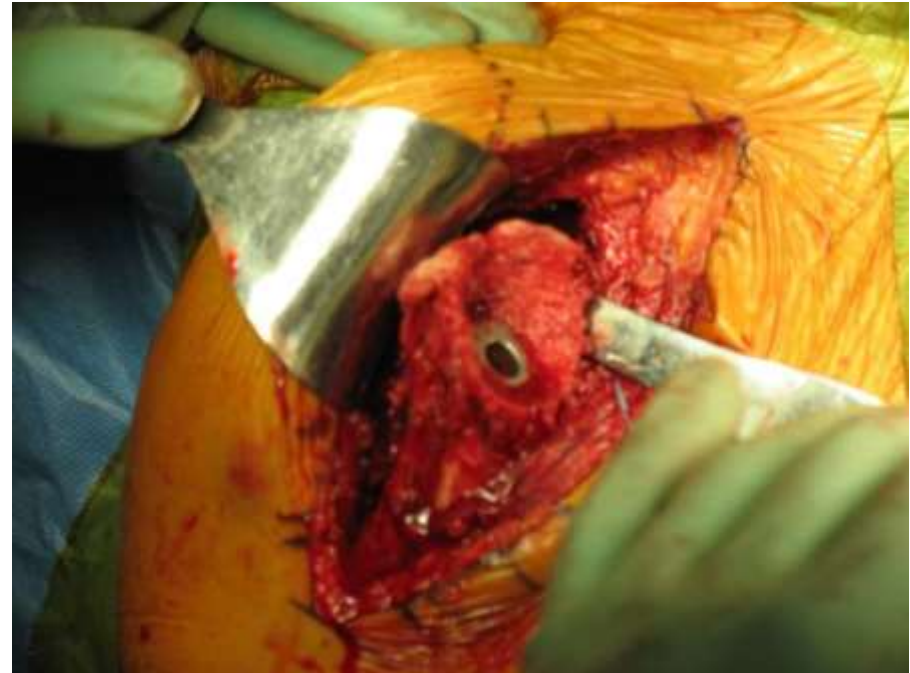- Positioning
- Approach
- Exposure
- **Humeral part**
- Glenoid part
- Soft Tissue closure

Version: 0 - 40



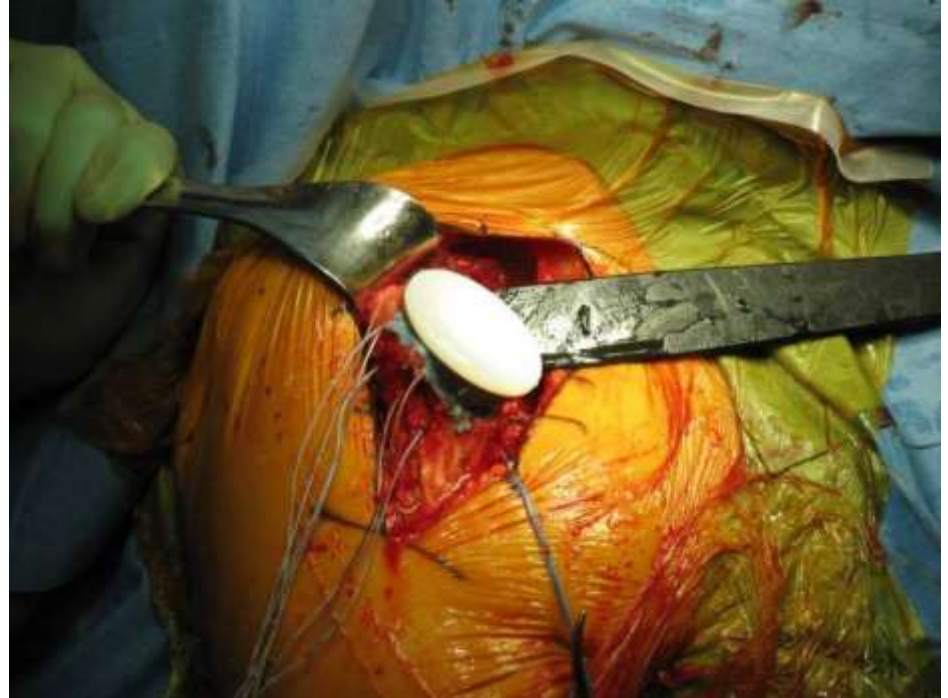Technique

- Positioning
- Approach
- Exposure
- **Humeral part**
- Glenoid part
- Soft Tissue closure



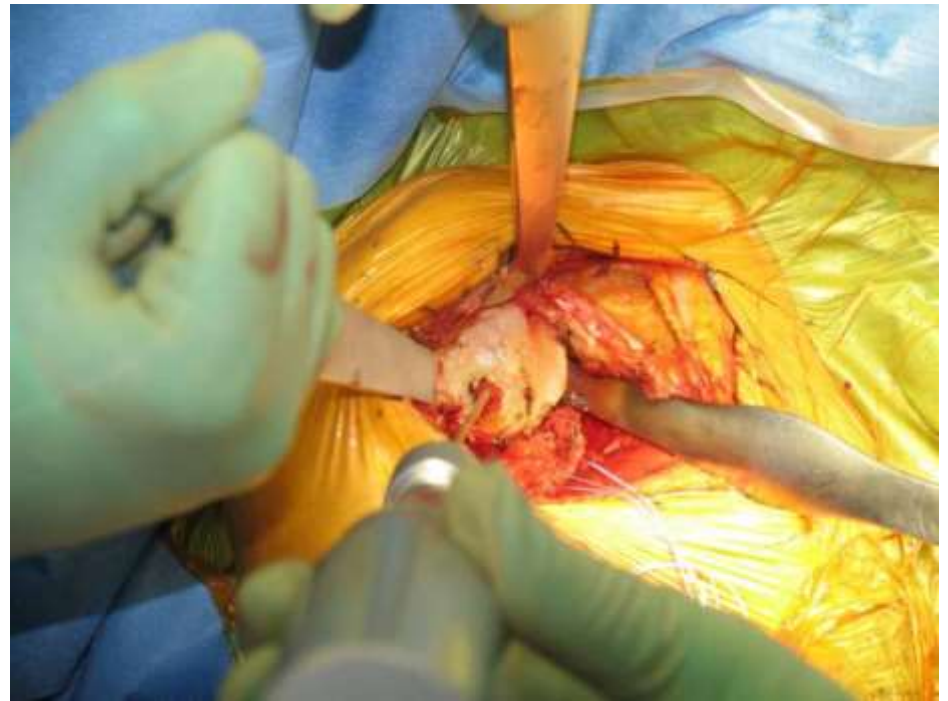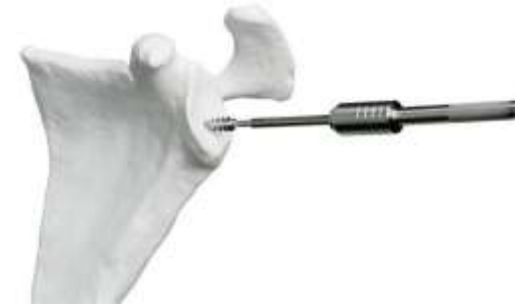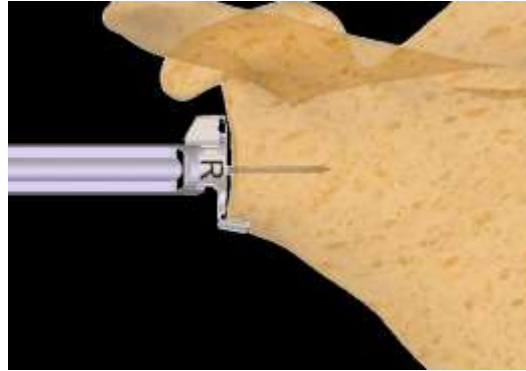
Technique

- Positioning
- Approach
- Exposure
- **Humeral part**
- Glenoid part
- Soft Tissue closure



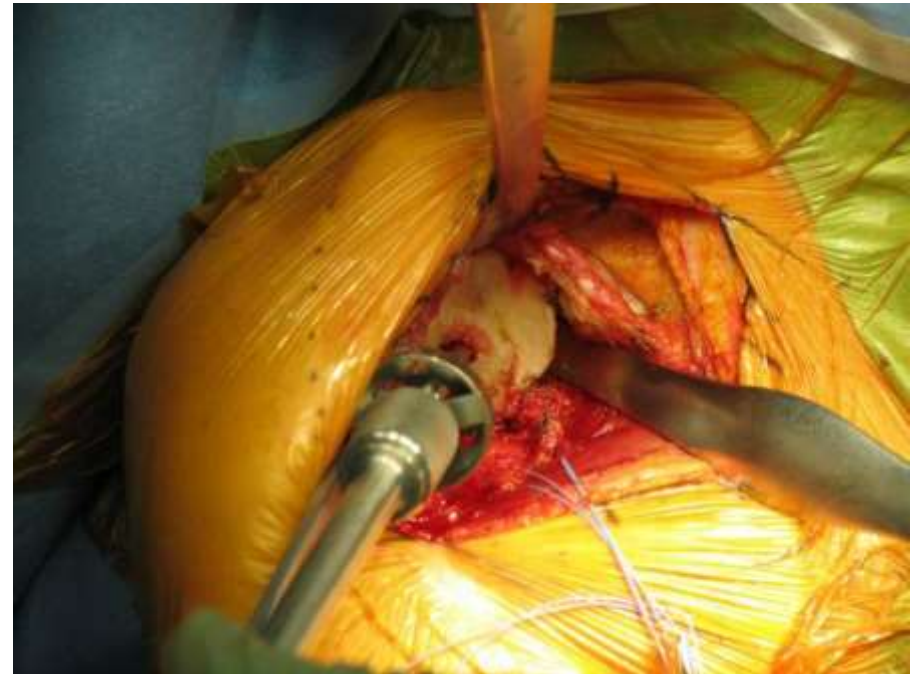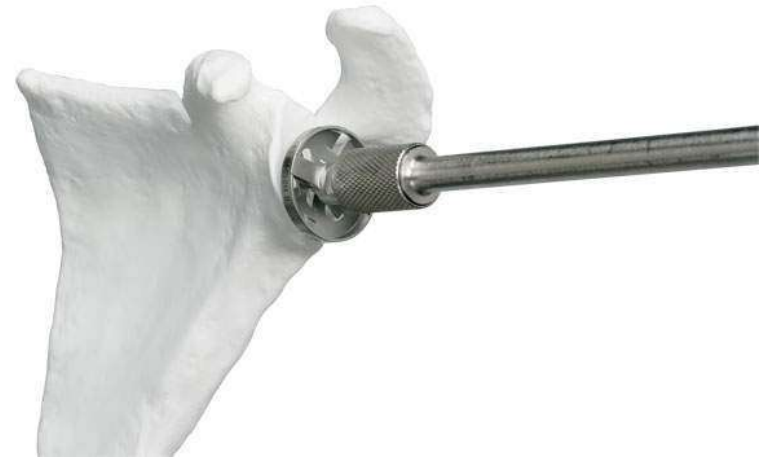Technique

- Positioning
- Approach
- Exposure
- Humeral part
- **Glenoid part**
- Soft Tissue closure



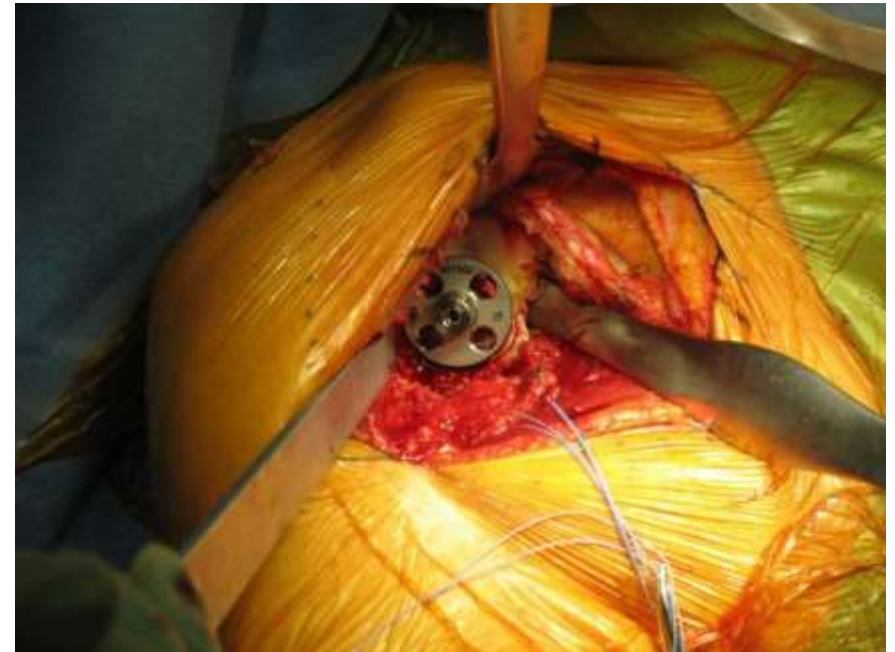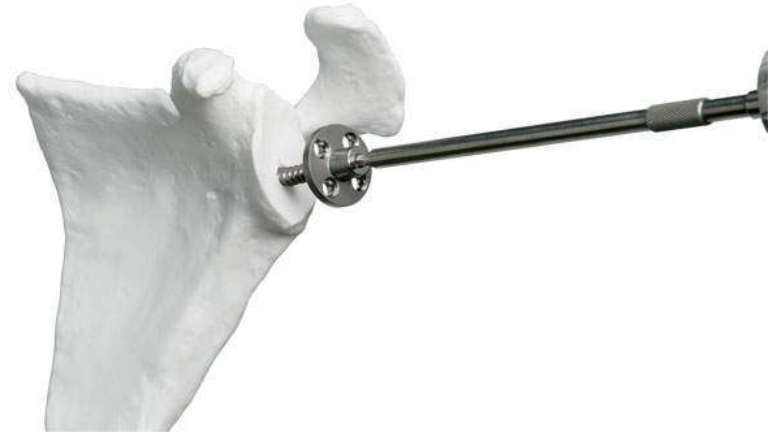Technique

- Positioning
- Approach
- Exposure
- Humeral part
- **Glenoid part**
- Soft Tissue closure



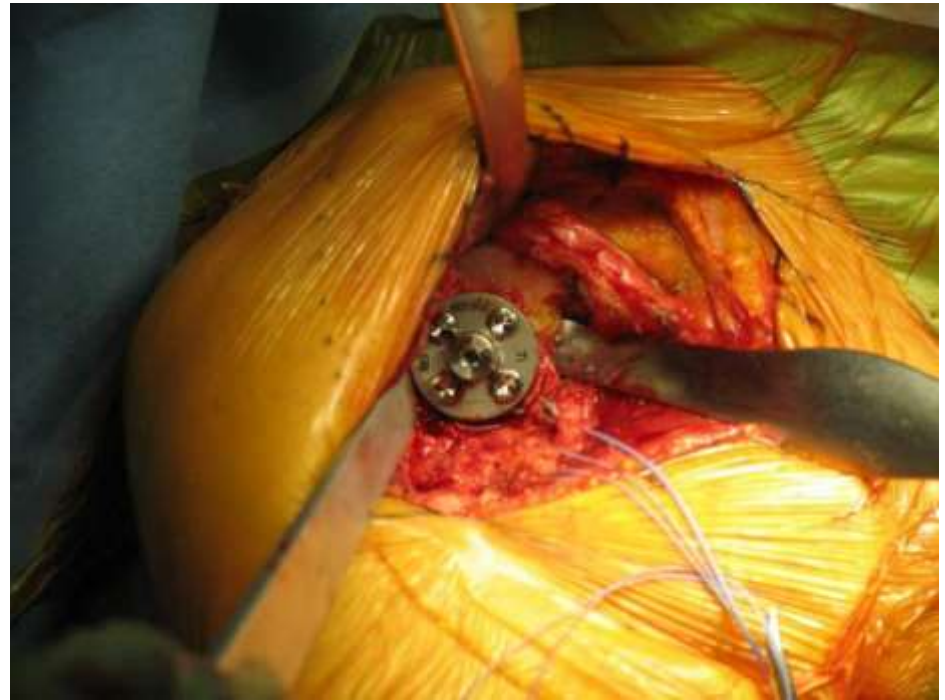Technique

- Positioning
- Approach
- Exposure
- Humeral part
- **Glenoid part**
- Soft Tissue closure



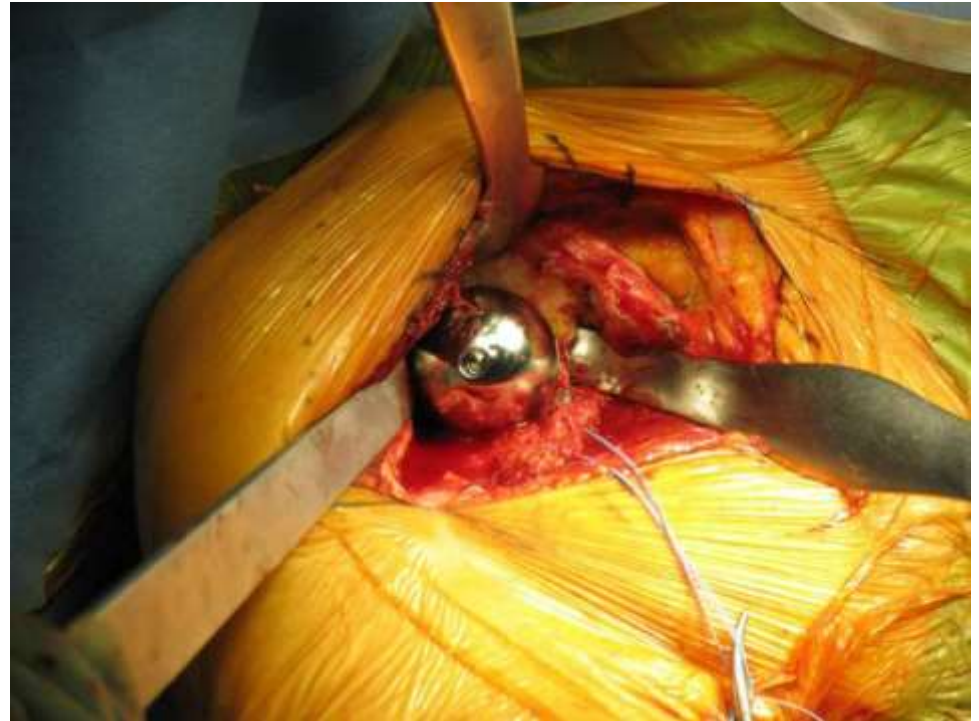Technique

- Positioning
- Approach
- Exposure
- Humeral part
- **Glenoid part**
- Soft Tissue closure



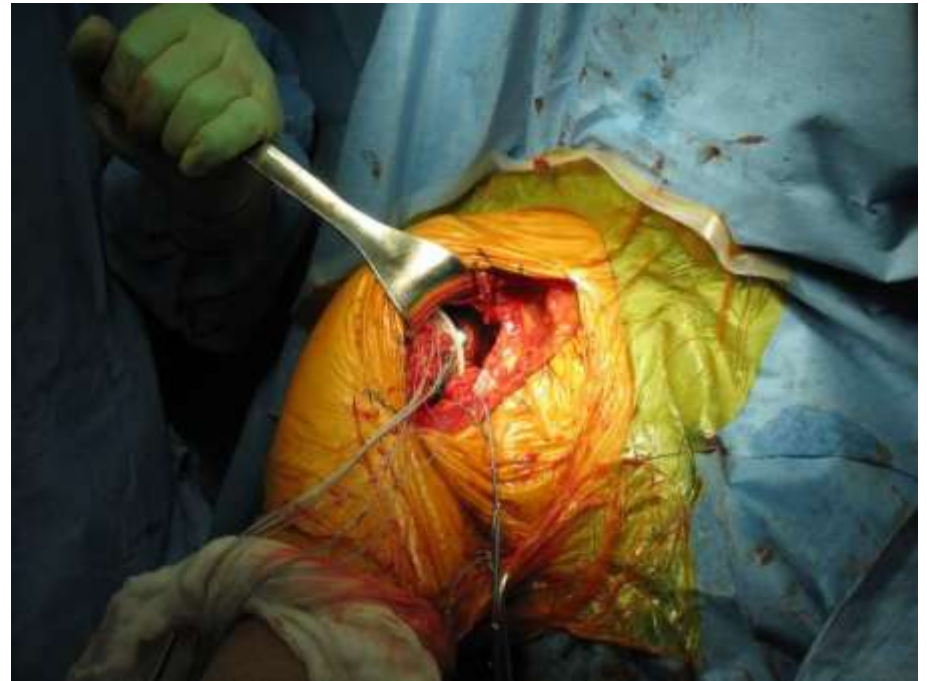
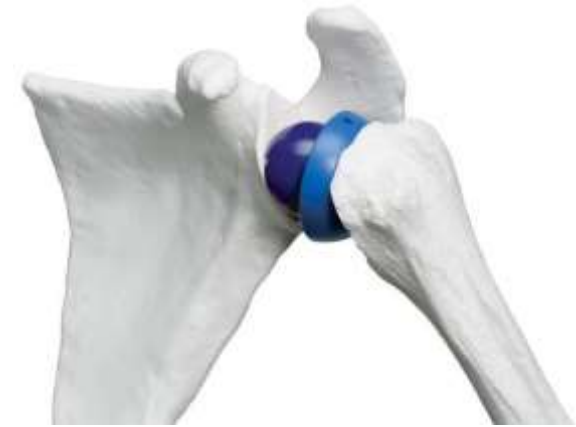Technique

- Positioning
- Approach
- Exposure
- Humeral part
- **Glenoid part**
- Soft Tissue closure



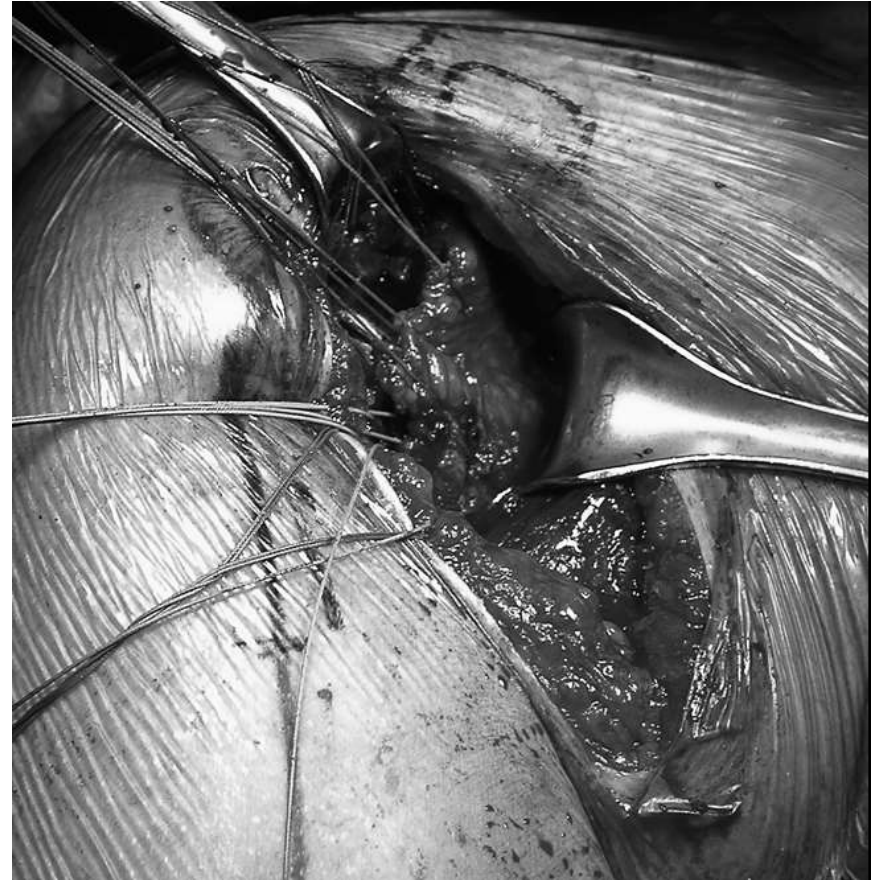Technique

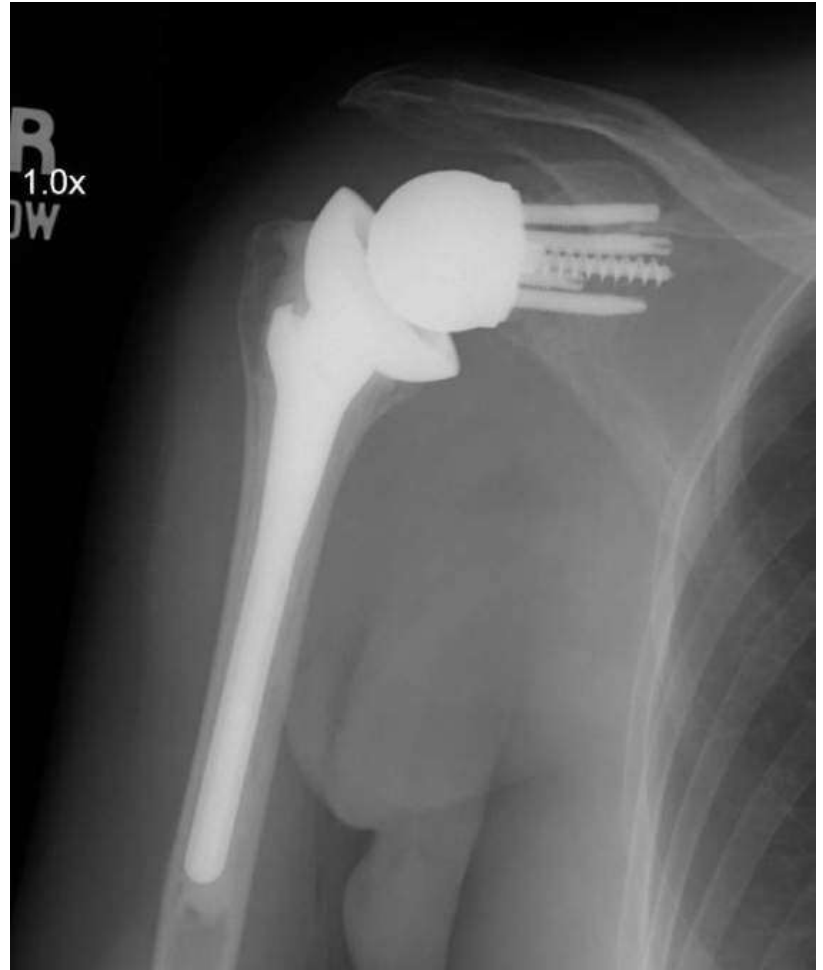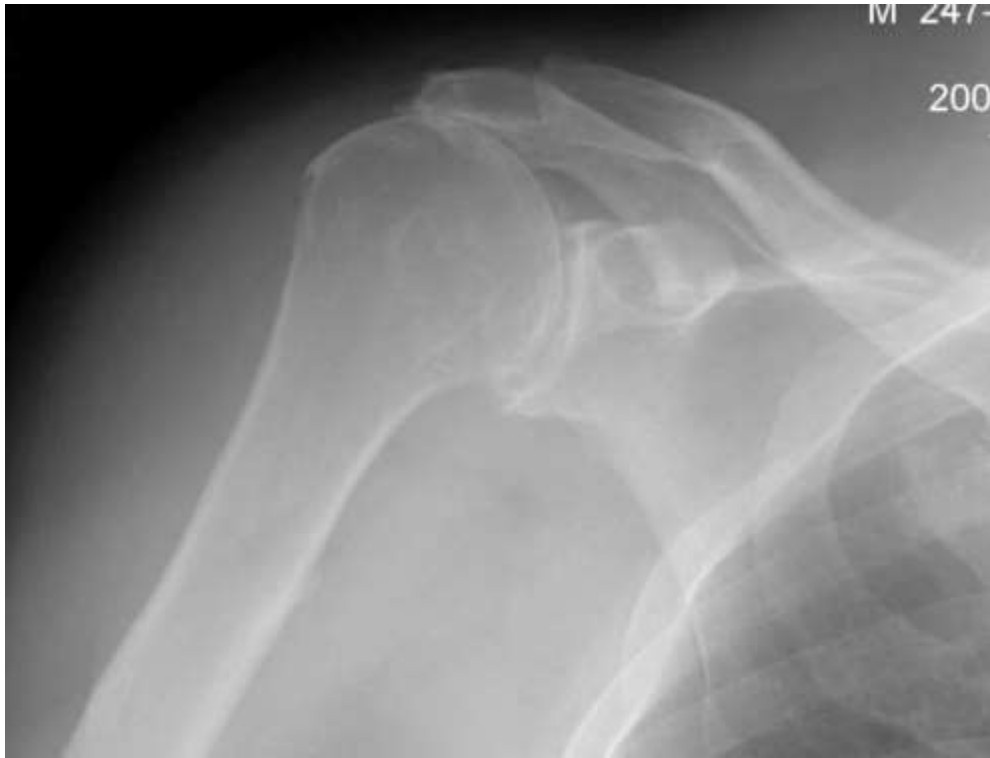- Positioning
- Approach
- Exposure
- Humeral part
- **Glenoid part**
- Soft Tissue closure



Technique

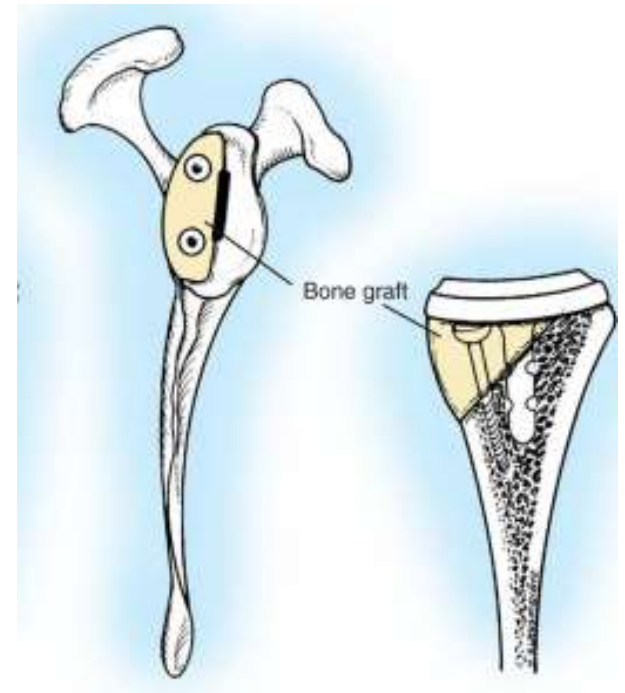
- Positioning
- Approach
- Exposure
- Humeral part
- Glenoid part
- **Soft Tissue closure**



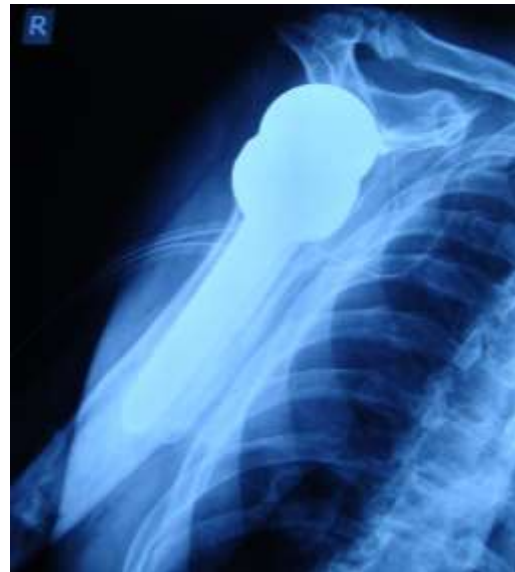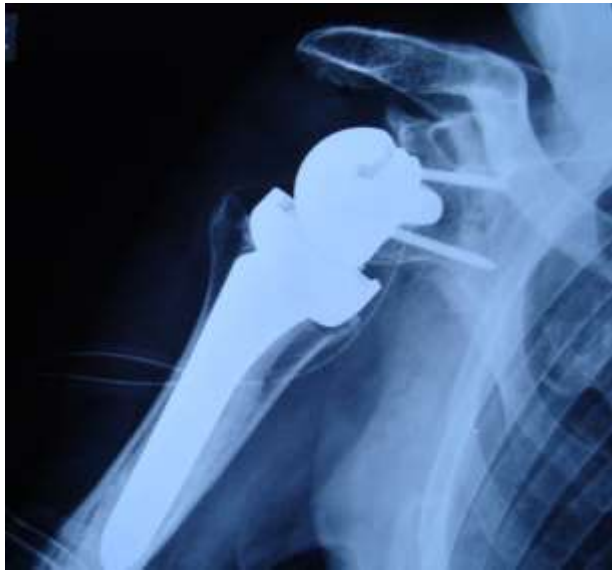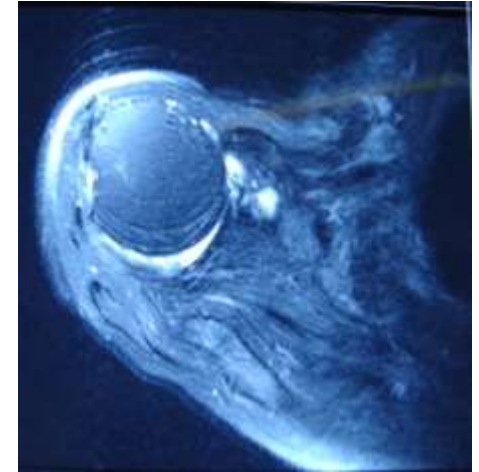
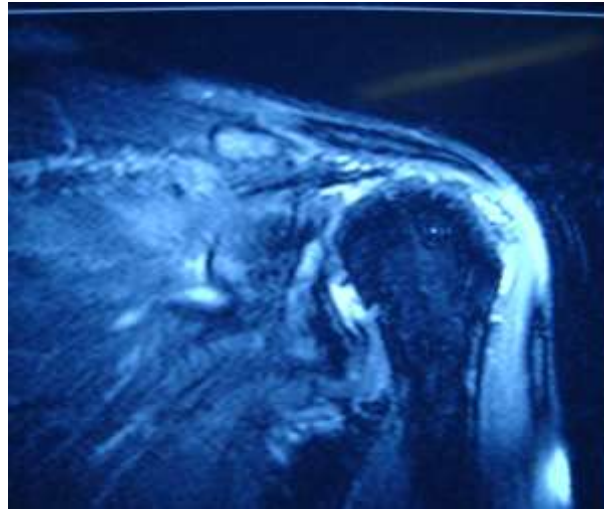


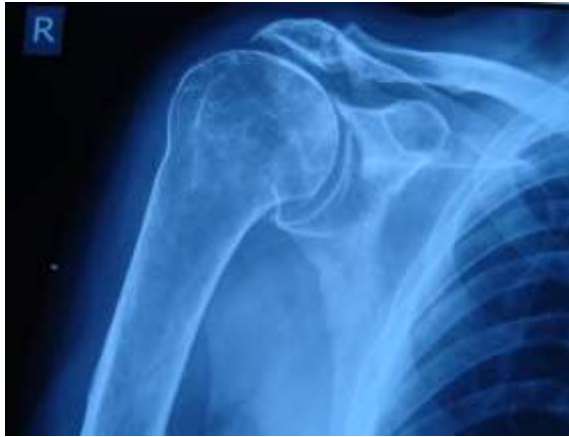Glenoid bone loss

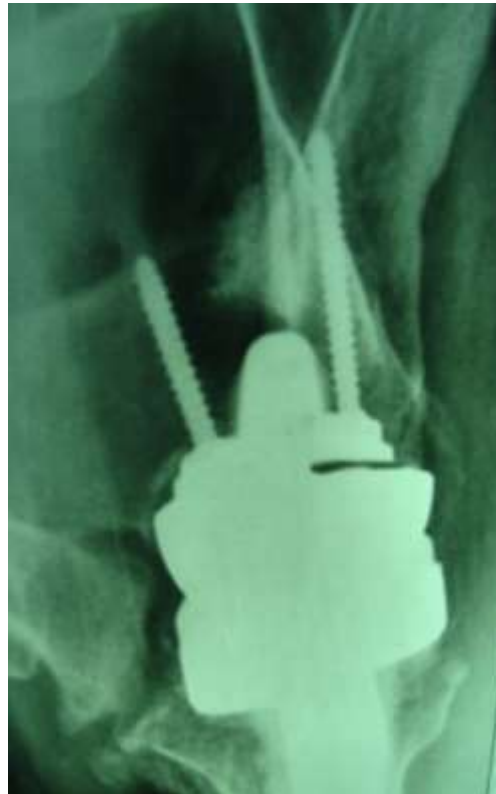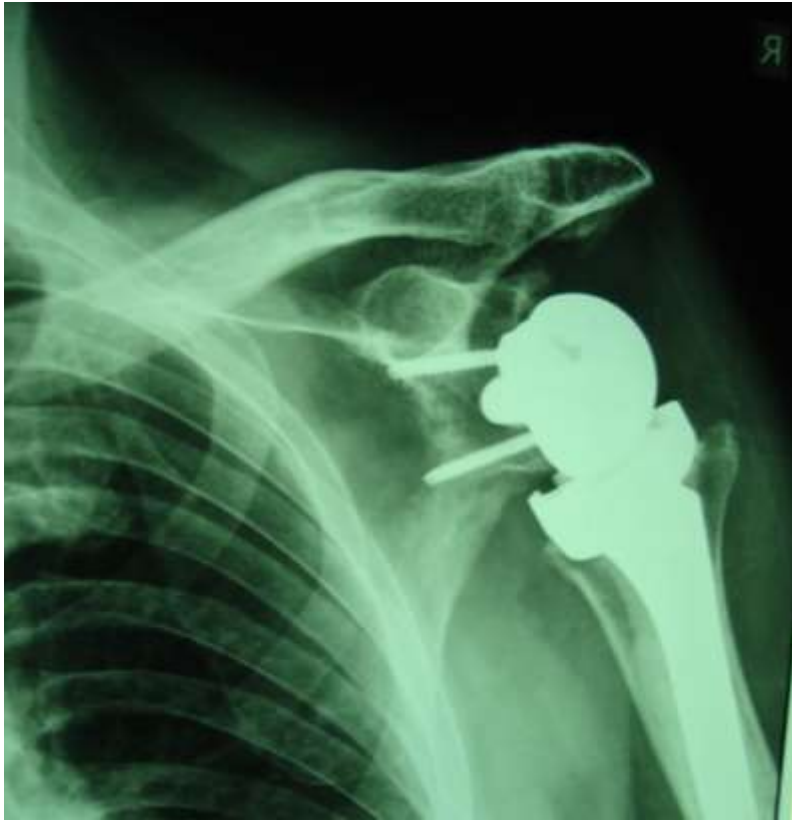- Challenging situation
- In revision surgery is not rare
- Bone grafting may be necessary for placement of the baseplate



78 y. male

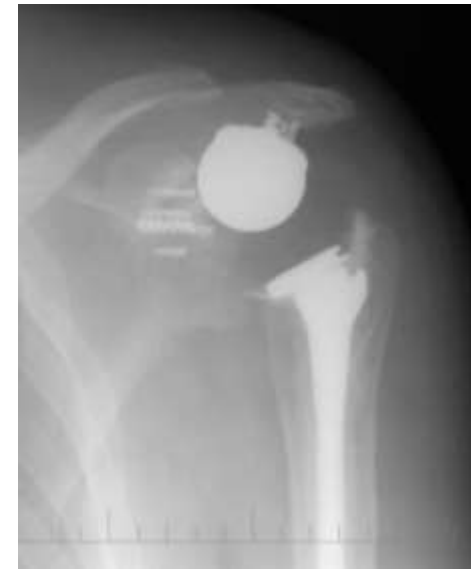
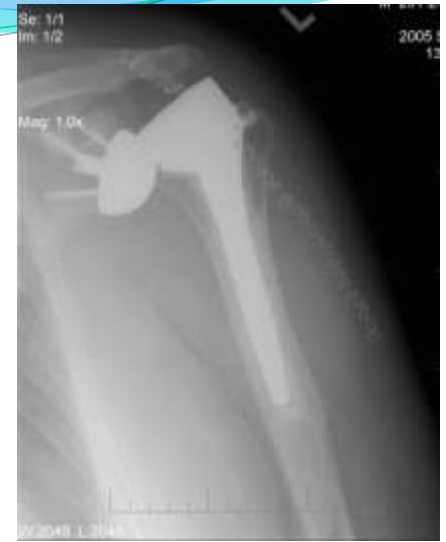
3 month post op



Summary

- **Meticulous notice to technique**
 - **Medialization, Stability of center of rotation**
- **Beware of complications**
 - **Hematoma, Acromial fracture, Instability, Infection**
 - **Late occurrence of inferior Scapular Notching.**



Thank you for attention