

Elbow arthroscopy

M.N. Naderi, MD

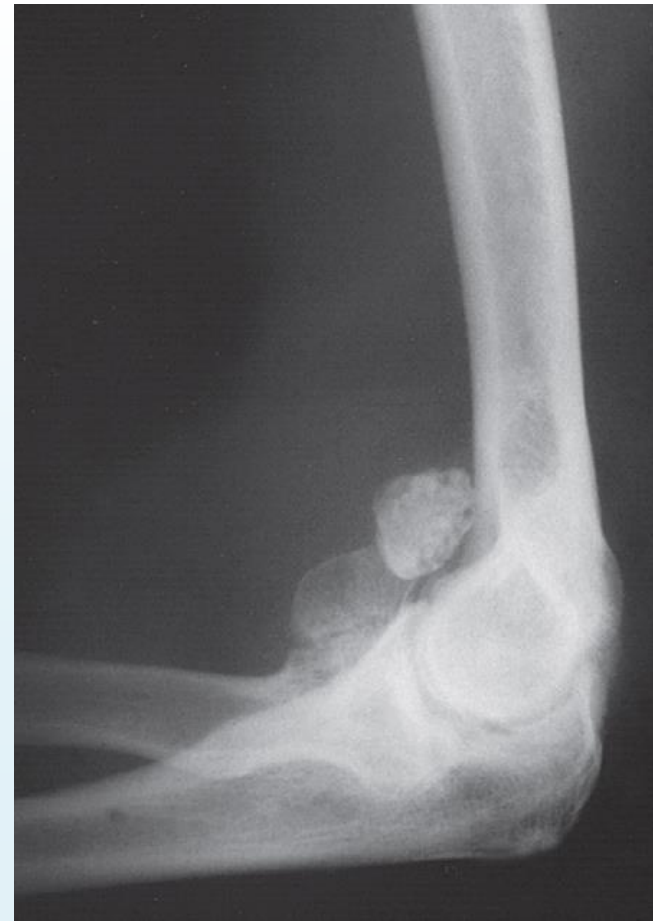

Indications

- ▶ loose bodies
- ▶ Adhesions
- ▶ Arthritis
- ▶ Stabilization procedures
- ▶ some intraarticular fractures

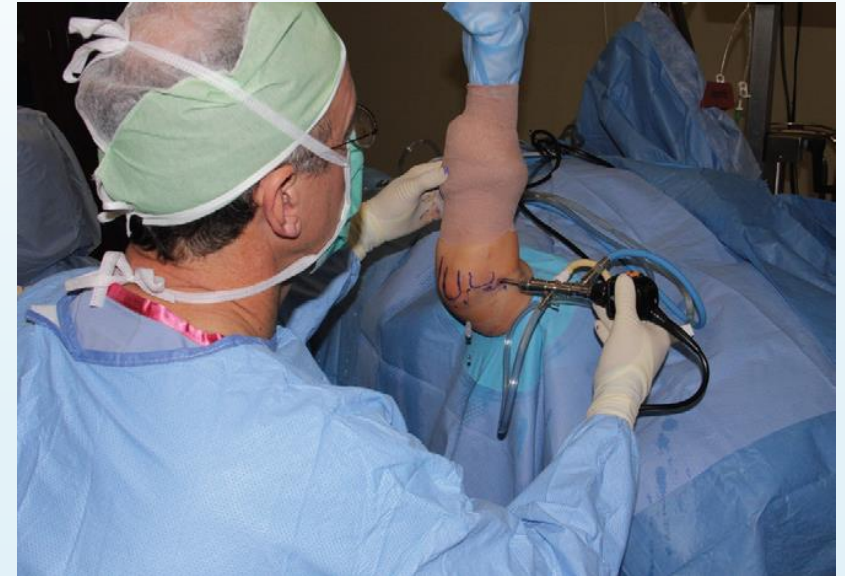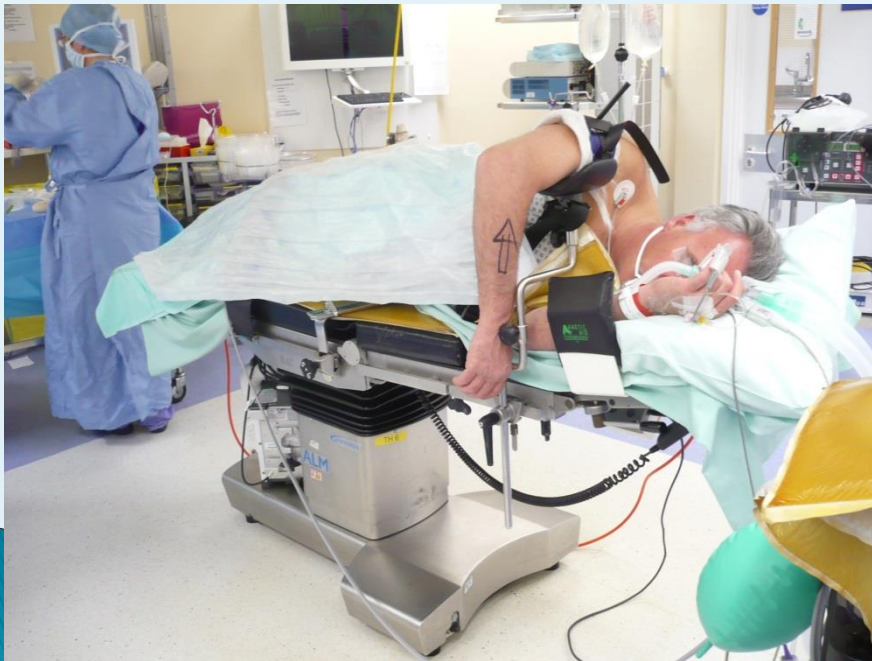Contraindications :

- bony or fibrous ankylosis
- anterior transposition of the ulnar nerve
- periarticular infection

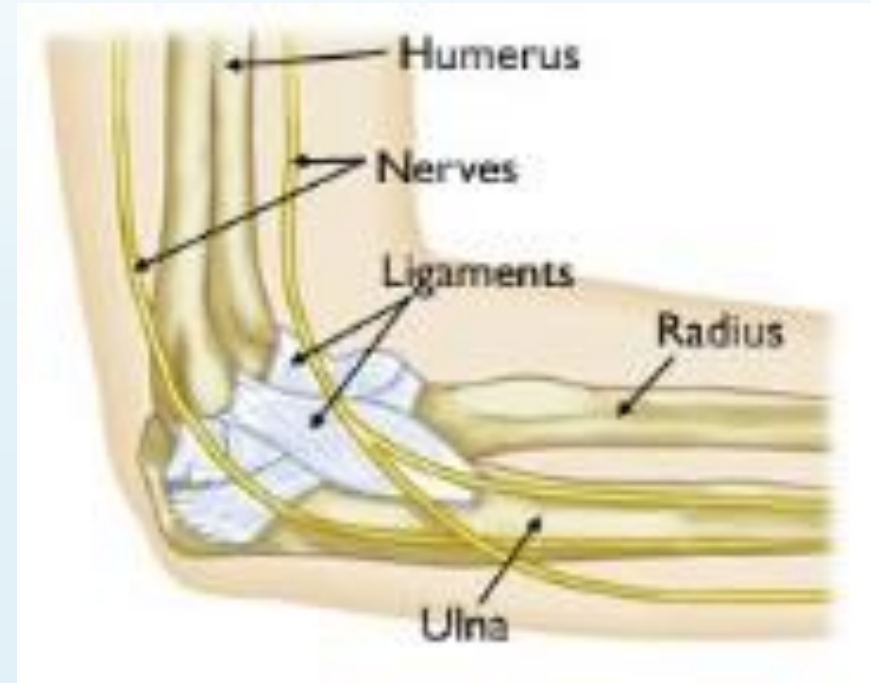
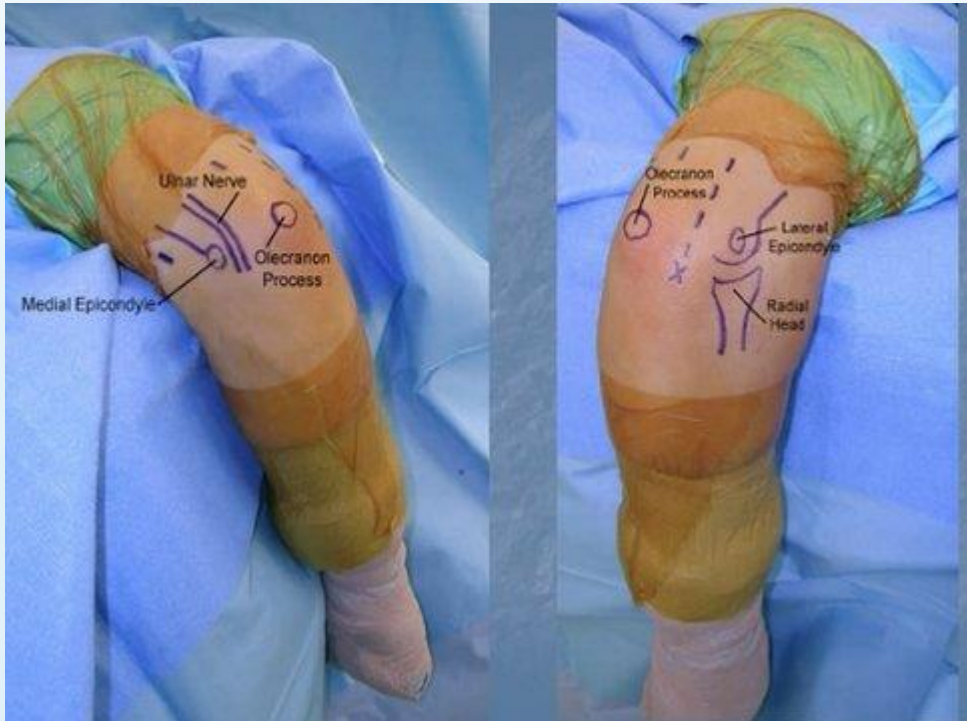


Position

- ▶ Supine
- ▶ Prone
- ▶ lateral decubitus

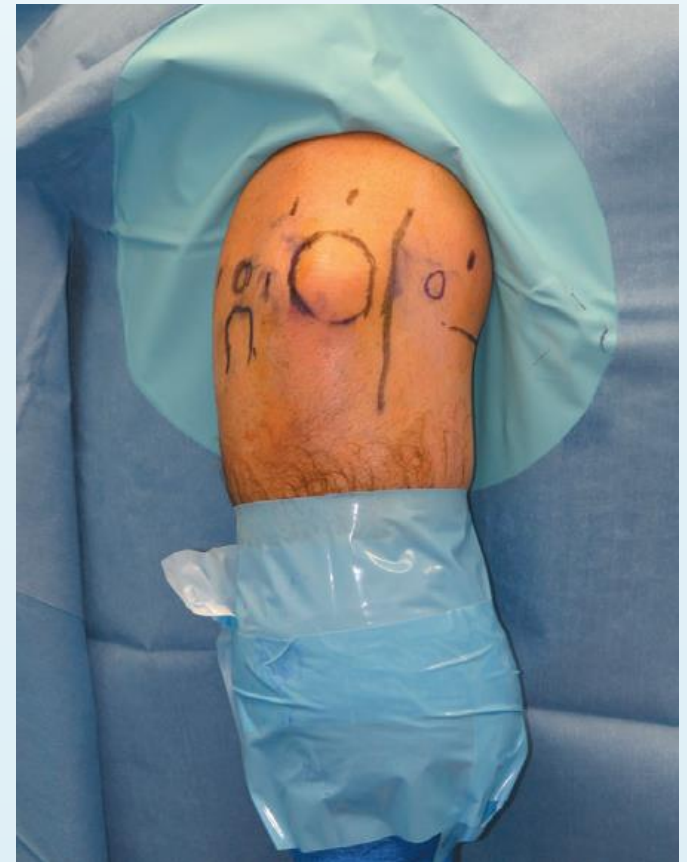
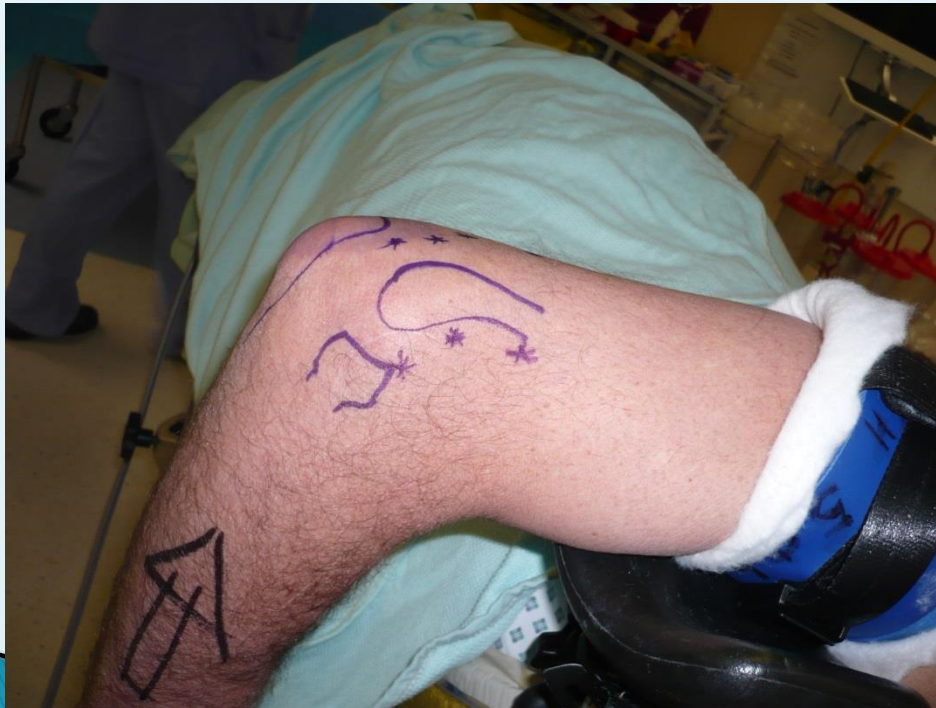

Anatomical considerations

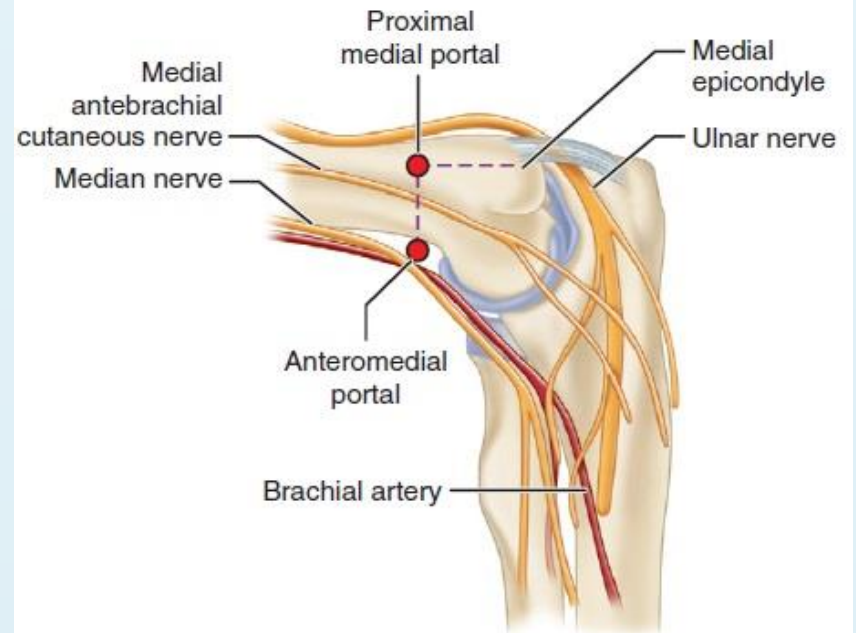
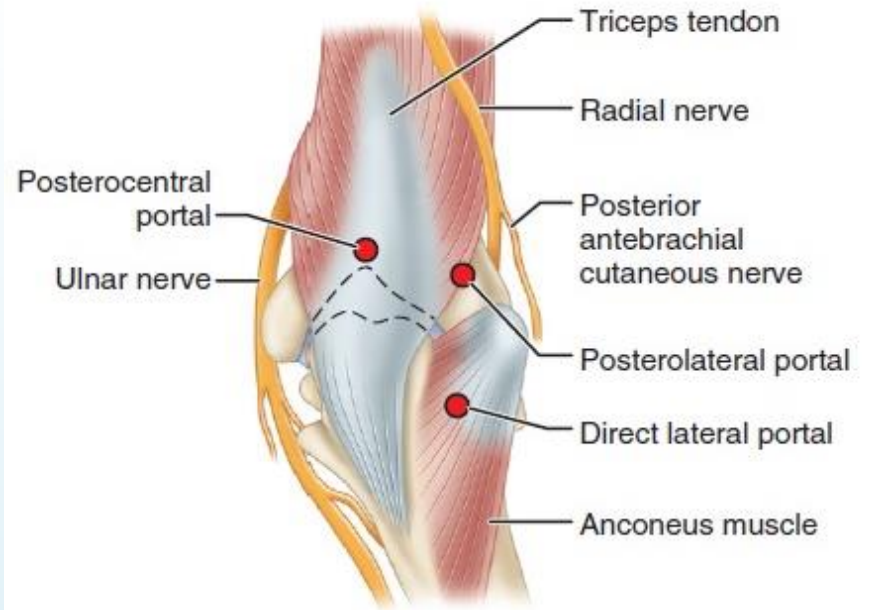
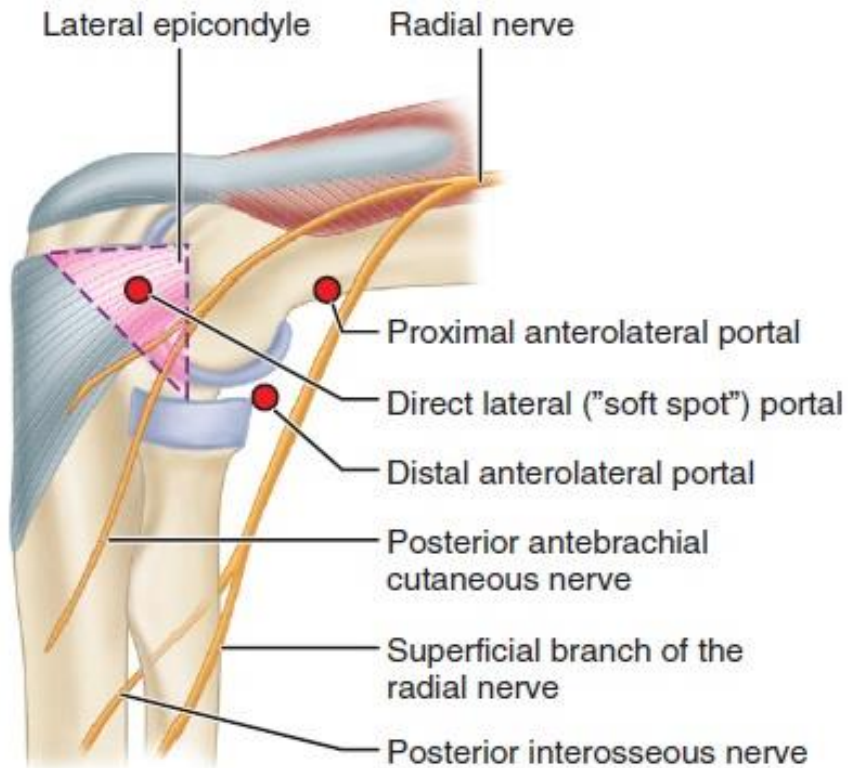


portals

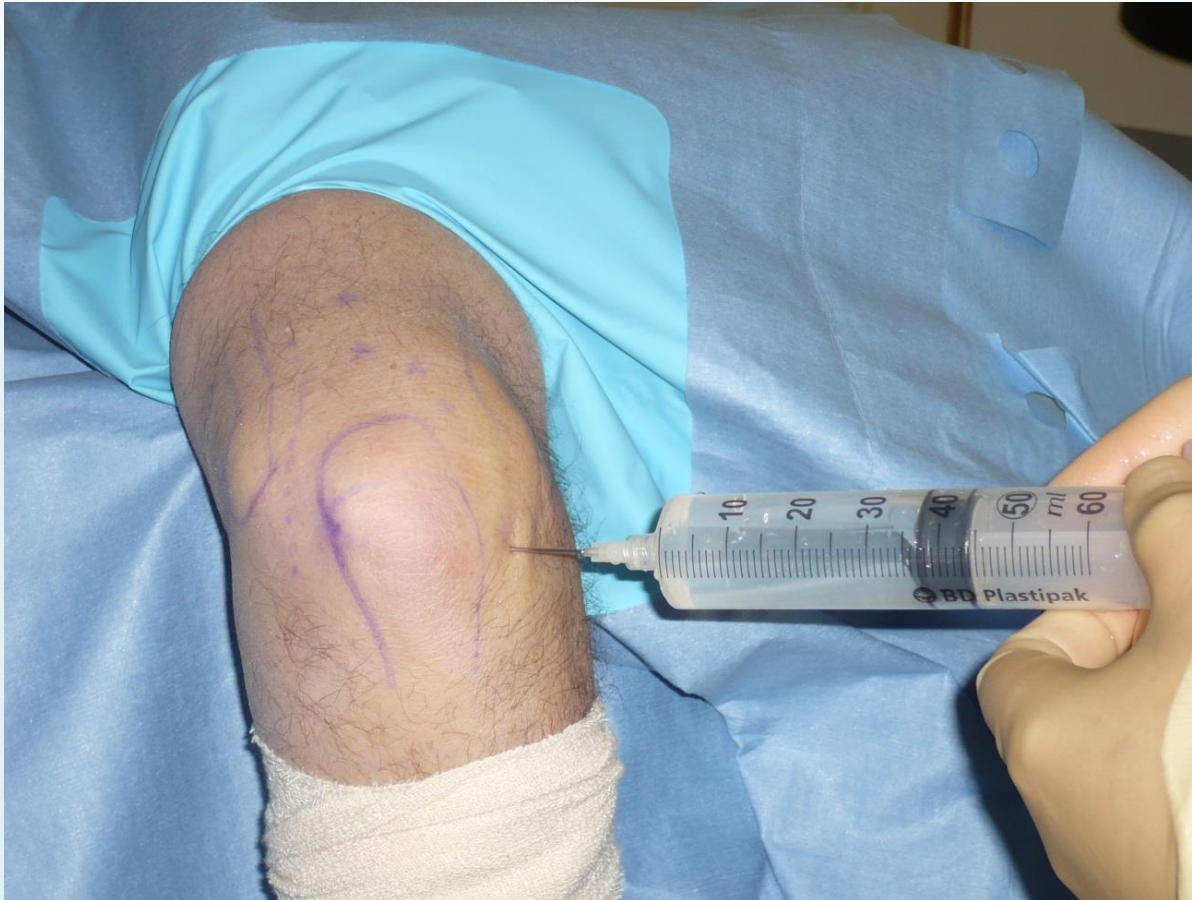- ▶ anterolateral portal (standard diagnostic Portal)
- ▶ Proximal medial portal
- ▶ posterior and posterolateral portals



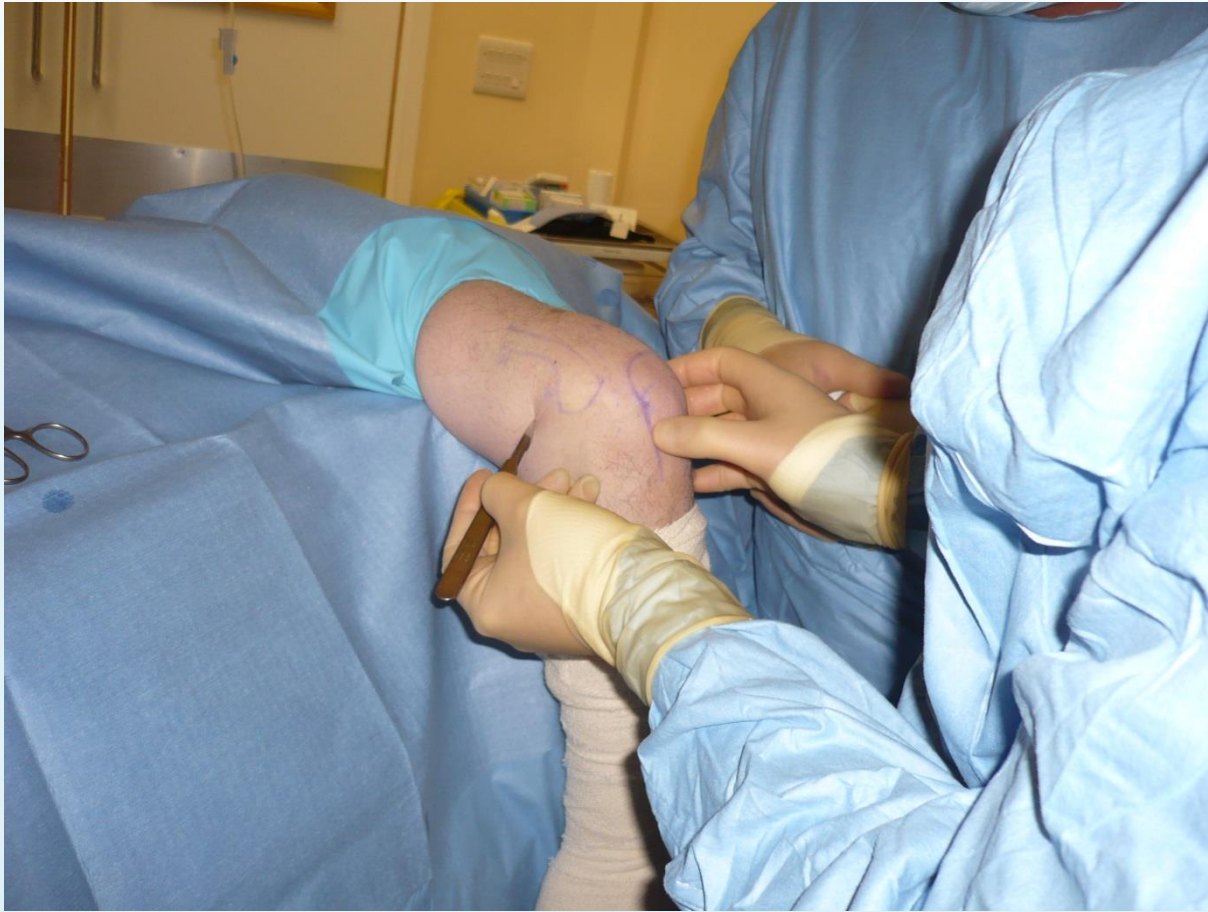portals



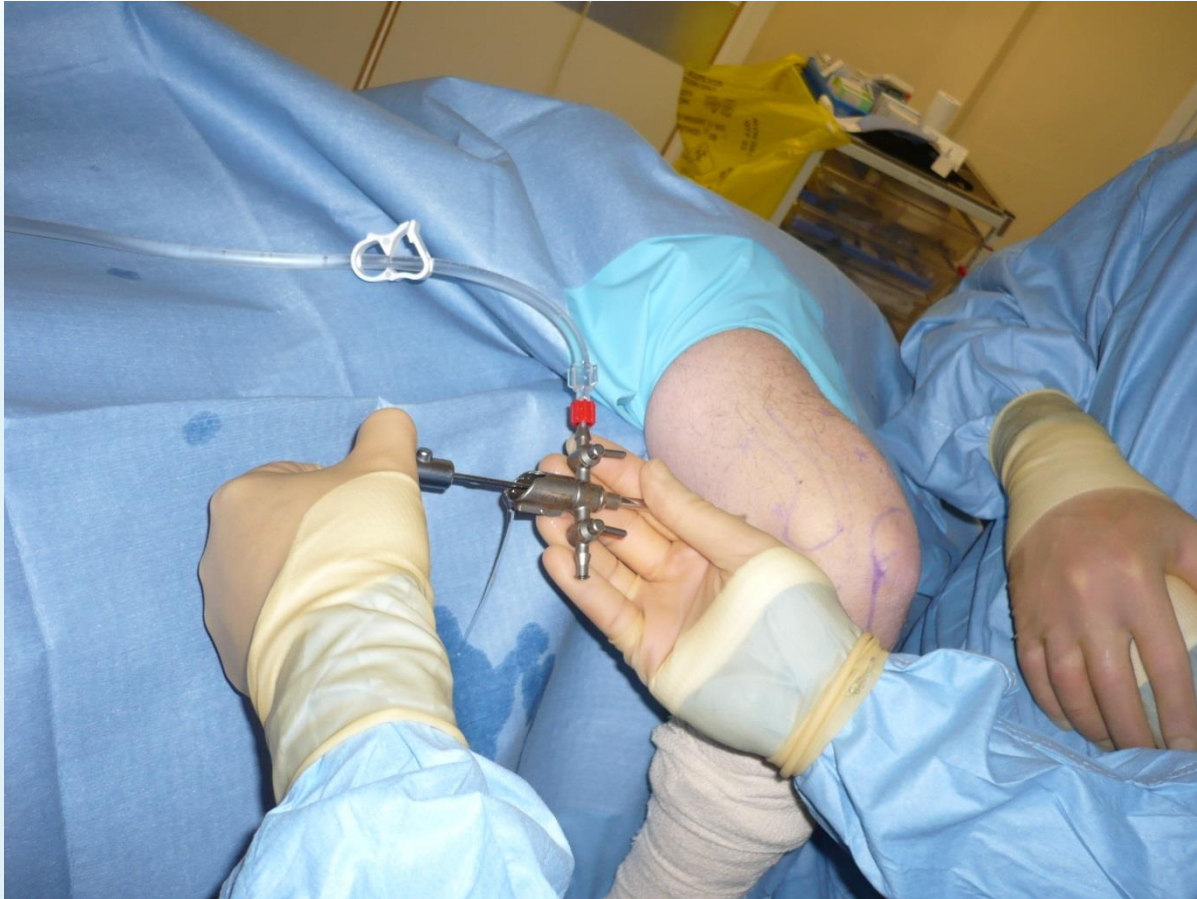Technique



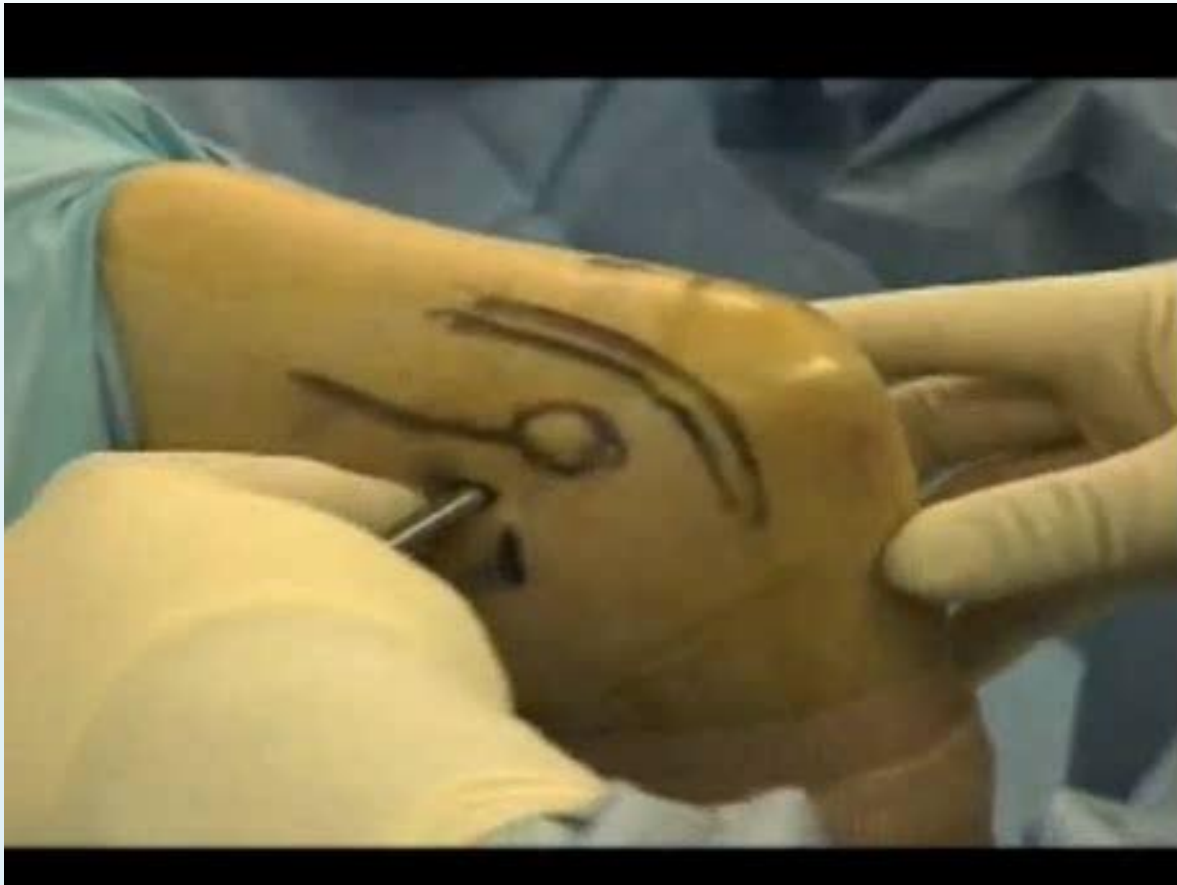Technique



Technique

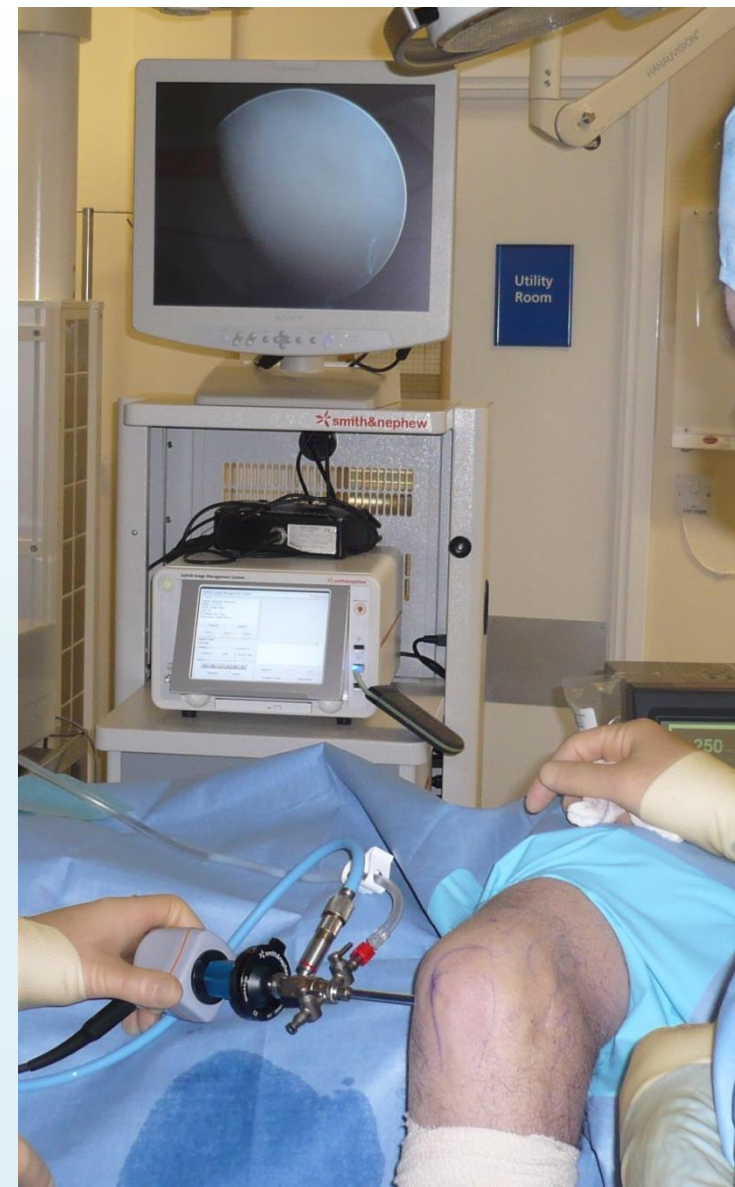

Technique



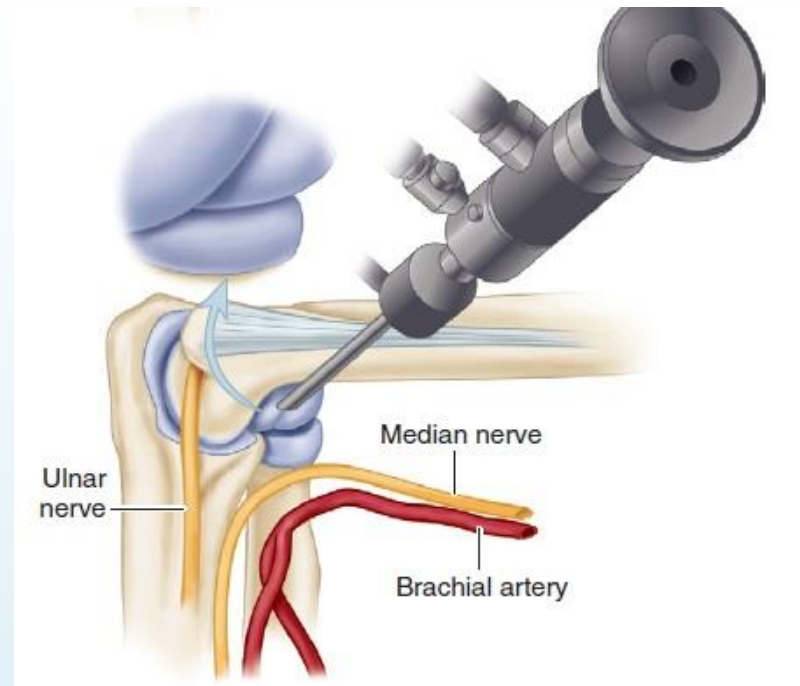
Complications

- ▶ Infection
- ▶ Instrument breakage
- ▶ Iatrogenic scuffing of articular surfaces
- ▶ tourniquet problems
- ▶ Neurovascular injuries (most common)



Summary

- ▶ Improve safety
 - Knowing anatomy
 - Time/distention limit
 - Arthroscopy skill
- ▶ Start with easiest procedures
- ▶ Convert to open when necessary



Thank you for your attention